

Comparison of Ultrasonography and Conventional Radiography in the Diagnosis of New Nasal Bone Fractures in Adults

Abdolhosayn Masoomi¹, Mohamad Momen Gharibvand²,
Hossien Rekabi¹, Mohsen Zakaeifar³, Elahe khorami³ and Nader Saki^{1*}

¹Head and Neck Surgery, Hearing Research Center, Ahvaz Jundishapur University of Medical Sciences, Ahvaz, Iran.

²Hearing Research Center, Ahvaz Jundishapur University of Medical Sciences, Ahvaz, Iran.

³Otolaryngologist, Hearing & Speech Research Center,
Ahvaz Jundishapur University of Medical Sciences, Ahvaz, Iran.

DOI: <http://dx.doi.org/10.13005/bbra/1598>

(Received: 05 February 2015; accepted: 10 March 2015)

Nasal bone fracture is the most commonly seen facial fracture. Conventional nasal radiography, in some cases, cannot help its diagnosis. Recently ultrasonography has been used to diagnose these fractures. The diagnosis is made by physical examination. The aim of this study was comparison of ultrasonography and conventional radiography in the diagnosis of new nasal bone fractures in adults. This study is a prospective study which was performed among 124 patients more than 15 years old suffering from new nasal bone fractures. The sonographer was not aware of the results of clinical examinations and conventional nasal radiographies. The bilateral nasal radiography, waters view and nasal bone ultrasonography were carried out in all patients and the results were compared to the patient's clinical examinations. In diagnosis of nasal dorsum fracture, lateral X-Rays sensitivity was 64% and specificity was 77.1% (P-Value < 0.05) and ultrasound sensitivity was 95.5% and specificity was 97.1% (P-Value = 0.375). In diagnosis of nasal lateral fracture, Waters view sensitivity was 53.7% and specificity was 78.6% (P-Value = 0.375) and ultrasound sensitivity was 88.9% and specificity was 98.6% (P-Value = 0.125). We found that in diagnosis of nasal bone fractures in adults, ultrasonography is more sensitive and specific than conventional X-Rays. Therefore according to our experiences, ultrasonography is superior over conventional X-Rays in the diagnosis of new nasal bone fractures in adults.

Key words: Nasal Fractures, Lateral Nasal X-Ray, Waters View, Ultrasonography.

Nasal bone fractures are the most common fractures in the maxillofacial trauma in human. The diagnosis is made by physical examinations. Symptoms and signs of nasal bone fractures include: nasal deformity (nasal asymmetry, nasal deviation), tenderness, epistaxis, nasal swelling, nasal obstruction, local pain or headache,

periorbital ecchymosis, nasal bone instability and crepitation. However these symptoms and signs may be transient or may not be seen. In most patients after trauma, created edema covers partial deformities and may prevent evaluation of crepitation and nasal bone instability. Reexamination of the patient 2 or 3 days later will allow for better appreciation of these deformities after swelling has decreased. Reduction commonly is done 7 days (before 10 days) after trauma under local or general anesthesia^{1,9,11}.

* To whom all correspondence should be addressed.
E-mail: Ahvaz.ent@gmail.com, Saki-n@ajums.ac.ir

Despite clear evidence that plain films do not have a role in the management of nasal fractures, these studies are frequently obtained to evaluate individuals after nasal trauma^{1,2,3}. Radiographies commonly include lateral nasal X-Ray to evaluate nasal dorsum and Occipitomental or Waters views to evaluate lateral nasal walls. The main criticism about the conventional radiographies is unacceptable level of predictive value because of several false positive and negative results from them. An investigation by de Lacey *et al.* showed that 66% of control subjects had a false-positive x-ray diagnosis using Waters (occipitomental) view radiographs¹. Clayton and Lesser reported that 25% (7 of 28) of their patients required surgical intervention on clinical grounds despite having negative x-ray reports². In a child, x-ray evaluation of nasal trauma proves to be of even less value than in the adult. On the other hand reduction in children should be carried out under general anesthesia. The other problem is probable injuries caused by surgical interferences in children. Therefore proper diagnosis before reduction is more fundamental in children^{6,12}.

Another which recently has been used to diagnose these fractures is ultrasonography, a common easy method involving no additional radiation exposure. The value of ultrasonography as a diagnostic tool for the detection of "bone" fractures (For example, in congenital hip dislocation, fractures of the radial or clavicular bone, or fractures of the ribs or skull) has been proven in various studies^{4,5,6,7}. It can be carried out early after trauma. In addition, many images could be taken from one patient, with minimal discomfort to the patient and usually the patient cooperation is not needed. Most centers can do it. It can be carried out by an otolaryngologist and it can be done during pregnancy^{7,8,10}.

Diagnosis of nasal bone fractures is usually done clinically early after trauma. In this situation development of edema makes accurate evaluation difficult. Ultrasonography can be carried out for such evaluation^{7,11}.

The aim of this study was comparison of ultrasonography and conventional radiography in the diagnosis of new nasal bone fractures in adults. Practical purposes include:

- 1) The use of ultrasonography for early diagnosis of nasal fractures.

- 2) Replacing plain X-Ray by ultrasonography as a first paraclinical step in the diagnosis of nasal fractures.
- 3) The use of ultrasonography in the diagnosis of nasal fracture can be invoked for documented recorded in forensic issues.
- 4) The use of ultrasonography is cases in which plain X-Ray is contraindicated, such as pregnancy.

Methods

This study is a prospective study which was performed among 124 patients more than 15 years old suffering from new nasal bone fractures. From September to December 2011, 152 patients over 15 years old who had nasal fracture clinically were evaluated in Imam Khomeini Hospital (Iran, Ahvaz University). All patients were evaluated clinically during the first hours after trauma and 3-4 days later by otolaryngologists. Twenty four (24) patients were excluded because of a history of an old fracture and 4 patients were excluded because of a history of rhinoplasty. So 124 patients were evaluated. During the first day after trauma, in all patients, bilateral nasal X-Rays, waters X-Ray and nasal bone ultrasonography were carried out and the results were compared to the patient's clinical examinations. (Figure 1 and 2) Sonographer was not aware of results of clinical examinations and nasal X-Rays. Sonographer used the 10 MHz **linear ultrasound** transducer probe in this study (Zimens Adara G40 Ultrasound, Germany). Statistic analysis was done by McNemar test.

RESULTS

One hundred and twenty four (124) patients, between 15 – 61 year old (Mean age 24.6), with a history of new nasal trauma and clinical sign of nasal bones fracture, without a history of an old nasal bone fracture or nasal surgery, were evaluated by X-rays and ultrasonography. Nineteen (19) patients (15.3%) had dorsal and lateral wall fractures together, 70 patients (56.5%) had fracture of nasal dorsum only and 35 patients (28.2%) had lateral nasal wall fracture only. Thirty five (35) patients (28.2%) were Female and 88 patients (71.8%) were Male. The paraclinical results are shown in the tables 1 and 2.

Of 65 patient who had dorsal fracture in their radiography, 57 ones (87.7%) had dorsal

Table 1. Investigating nasal dorsum fracture in the patients

	Paraclinical Results	Clinically fractured		No clinical fracture	
		Number	Percent	Number	Percent
Lateral nasal bone X-Rays	Fracture	57	87.7	8	12.3
	No fracture	32	54.2	27	45.8
Ultrasonography	Fracture	85	98.8	1	1.2
	No fracture	4	10.5	34	89.5

Table 2. Investigating lateral nasal wall fracture in the patients

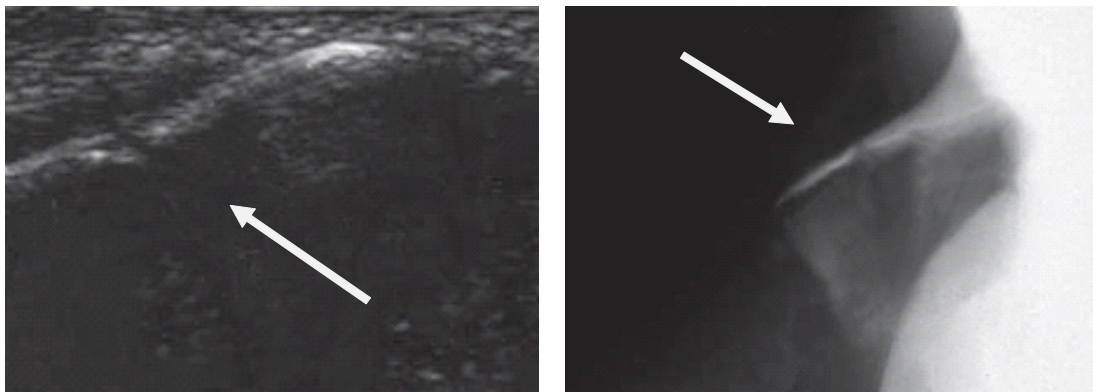
	Paraclinical Results	Clinically fractured		No clinical fracture	
		Number	Percent	Number	Percent
Waters view	Fracture	29	65.9	15	34.1
	No fracture	25	31.2	55	68.8
Ultrasonography	Fracture	48	98	1	2
	No fracture	6	8	69	92

fracture and 8 ones (12.3%) did not have dorsal fracture clinically. Of 59 patient who did not have dorsal fracture in their radiography, 32 ones (54.2%) had dorsal fracture and 27 ones (45.8%) did not have dorsal fracture clinically. For detection of fractures of nasal dorsum, lateral X-ray had 64% sensitivity and 77.1% specificity. There was a significant difference between the results of radiography and clinical diagnosis of fracture of the nasal dorsum in McNemar test (P -value < 0.05).

Of 86 patients who had dorsal fracture in their ultrasonography, 85 ones (98.8%) had dorsal fracture and 1 patient (1.2%) did not have dorsal fracture clinically. Of 38 patients who did not have dorsal fracture in their ultrasonography, 34 ones (89.5%) did not have dorsal fracture and 4 ones

(10.5%) had dorsal fracture clinically. For detection of fractures of nasal dorsum ultrasonography had 95.5% sensitivity and 97.1% specificity. There was not a significant difference between the results of ultrasonography and clinical diagnosis of fracture of the nasal dorsum in McNemar test (P -value = 0.375).

Of 44 patient who had lateral nasal wall fracture in their radiography, 29 ones (65.9%) had dorsal fracture and 15 ones (34.1%) did not have dorsal fracture clinically. Of 80 patients who did not have dorsal fracture in their radiography, 25 ones (31.2%) had lateral fracture and 55 ones (68.8%) did not have lateral fracture clinically. For detection of lateral nasal wall fractures waters X-ray had 53.7% sensitivity and 78.6% specificity.

**Fig. 1.** A 24-year-old man with a fractured nasal dorsum in lateral view of the nose and Ultrasonography

There was not a significant difference between the results of Waters X-Ray and clinical diagnosis of nasal wall fracture in McNemar test (P -value = 0.155).

Of 49 patients who had lateral nasal wall in their ultrasonography, 48 ones (98%) had lateral nasal wall fracture and 1 patient (2%) did not have dorsal fracture clinically. Of 75 patient who did not have lateral nasal wall fracture in their

ultrasonography, 69 ones (92%) did not have lateral nasal wall fracture and 7 ones (8%) had lateral nasal wall fracture clinically. For detection of lateral nasal wall fractures ultrasonography had 88.9% sensitivity and 98.6% specificity. There was not a significant difference between the results of ultrasonography and clinical diagnosis of lateral nasal wall fracture in McNemar test (P -value = 0.125).

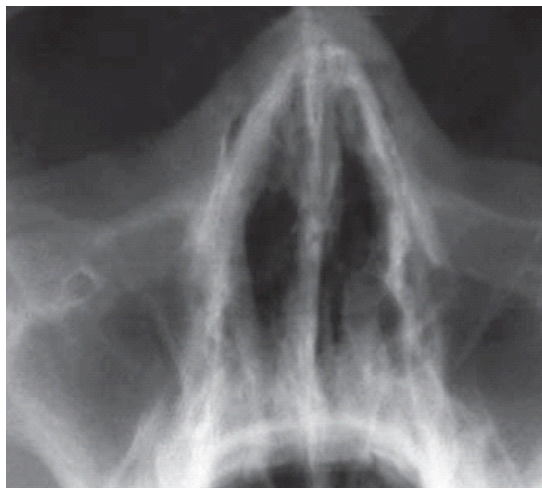
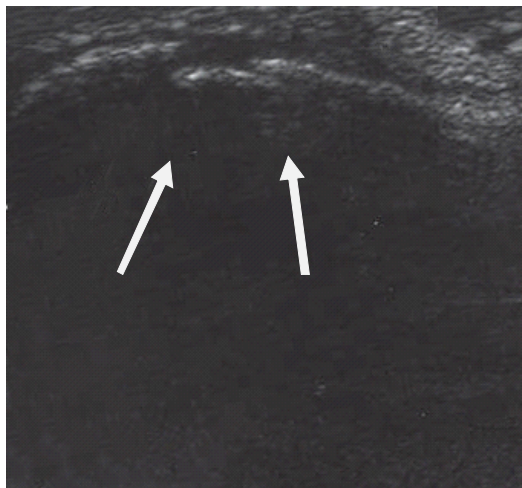


Fig. 2. A 28-year-old woman with a normal Waters view and a fractured left lateral nasal wall in ultrasonography

DISCUSSION

The judgment of otolaryngologists, early after trauma or 3-4 days later by careful clinical examinations is still the main criterion for the detection of nasal bone fractures. Sometimes examination under general anesthesia is needed to clarify the diagnosis^{1,9,11}. However, paraclinical tests are needed for documented recorded in forensic issues. Although plain X-Rays are routinely performed in many emergency and trauma centers for detection of nasal fractures, They seem to be unnecessary^{1,2,3}.

Recently ultrasonography has been used to detection these fractures. Ultrasonography is a common easy method involving no additional radiation exposure. The value of ultrasonography as a diagnostic tool for the detection of "bone" fractures (For example, in congenital hip dislocation, fractures of the radial or clavicular bone, or fractures of the ribs or skull) has been proven in various studies. It can be carried out early after trauma .In addition, many images could

be taken from one patient without radiation hazard, with minimal discomfort to the patient, and usually the patient cooperation is not needed. Most centers can do it. It can be carried out by an otolaryngologist and it can be done during pregnancy^{4,5,7,8,9,10,11}.

Beck *et al.* reported a study on 21 patients in1992 by ultrasound (5 MHZ and 7.5 MHZ probe). They demonstrated that ultrasonography and radiography have the same value in diagnosis of nasal fractures. But they did not compare their results with the clinical findings.⁸

Oliver Thiede *et al.* (Germany, 2005) using 10 MHZ probe, reported that assessment of the lateral nasal walls revealed that ultrasonography was statistically superior ($P = 0.04$) to radiography. In contrast, assessment of the nasal dorsum showed radiography to be statistically superior ($P = 0.01$) to ultrasonography. Assessment of the nasal pyramid revealed no statistical difference between radiography and ultrasonography ($P = 0.91$).⁹

Gürkov *et al.* (Germany, 2008) in a study on 80 patients reported that for detection of

fractures of the nasal dorsum, both modalities had high sensitivity (98 and 88% for US and XR, respectively) and specificity (95% for both US and XR). In lateral nasal wall fractures, specificity was higher for XR (75% versus 94%). Sensitivity was significantly higher for the US examination (98% versus 28%). The accuracy was higher for ultrasonography in their study.¹⁰ In our study in both fractures, dorsal and lateral fracture, the sensitivity and specificity was higher for ultrasound.

Tarek Fouad *et al.* (Egypt, 2009) reported that ultrasonography sensitivity was (97.74%) and specificity was (98.52%), while X-Ray sensitivity was (74.38%) and specificity was (87.79%) in diagnosis of nasal bone fractures. As our study they suggest that ultrasonography is superior to conventional X-Ray and can be useful tool for detection of nasal fractures.¹¹

In our study (By the 10 MHz ultrasound probe) for detection of fractures of nasal dorsum, bilateral nasal X-rays had 64% sensitivity and 77.1% specificity (P-value <0.05) and Ultrasonography had 95.5% sensitivity and 97.1% specificity (P-value =0.375). According to our results, for detection of fractures of nasal dorsum in adults, Ultrasonography is superior to lateral nose X-rays. For detection of lateral nasal wall fractures, waters view had 53.7% sensitivity and 78.6% specificity (P-value = 0.155) and Ultrasonography had 88.9% sensitivity and 98.6% specificity (P-value =0.125). According to our results, for detection of lateral nasal wall fractures Ultrasonography is superior to lateral nose X-rays. In summary, for detection of new nasal fractures in adults the accuracy was higher for Ultrasonography.

In our study, we have excluded children, patients with old nasal fractures and patients with history of nasal surgery and judging about them is upon carried out researches on these groups.

CONCLUSION

Based on previous studies and our results in diagnosis of nasal bone fractures in adults, ultrasonography is more sensitive, specific and accurate than conventional X-Rays. Therefore ultrasonography is superior over conventional radiography in the diagnosis of new nasal bone

fractures in adults and when conventional X-Ray and ultrasonography both are available, ultrasonography should be the first line imaging procedure in the evaluation of new nasal fractures in adults.

ACKNOWLEDGEMENTS

The authors would like to thank the research deputy of Ahavz Jundishapur University of Medical Sciences for their valuable cooperation.

REFERENCES

- Burke E. Sherard A. Nasal Fractures. *Cummings Otolaryngology* 2010;**1**(35):496-500.
- M. I. Clayton and T. H. J. Lesser. The role of radiography in the management of nasal fractures. Cambridge, *The Journal of Laryngol & Otol Surg*, 1986 ;**100**(7):797-802.
- Nigam A, Goni A, Benjamin A, Dasgupta AR. The value of radiographs in the management of the fractured nose. *Arch Emerg Med*. 1993; **10**: 293-297.
- Katz R, Landman J, Dulitzky F, Bar-Ziv J. Fracture of the clavicle in the newborn: an ultrasound diagnosis. *J Ultrasound Med*. 1988; **7**: 21-23.
- Klinger M, Danter J, Siegert R. Sonographie von Orbitabodenfrakturen: eine Alternative zur Computertomography *Laryngorhinootology*. 1996; **75**: 242-246.
- Poussaint TY, Moeller KK. Imaging of pediatric head trauma. *Neuroimaging Clin N Am*. 2002; **12**: 271-294, ix.
- Jank S, Strobl H, Emshoff R, *et al.* Bildgebende Diagnostik der medialen und lateralen Orbitawandfraktur: Sonographie versus Computertomographie. *Mund Kiefer Gesichtschir*. 2003; **7**: 208-213.
- Beck A, Maurer J, Mann W. Sonographische diagnose von nasenbeinfrakturen: otorhinolaryngologie. *European Archives of Oto-Rhino-Laryngology*.1992;**249**(7):404-440 1992:68.
- Oliver Thiede, MD; Jan-Hendrik Kromer, MD; Cludia Rudack, MD; Wolfgang stoll, MD; Nani Osada, MD; Frank Schmal, MD;. Comparison of Ultrasonography and Conventional Radiography in the Diagnosis of Nasal Fractures. *Arch Otolaryngol Head and Neck Surg*. 2005; **131**: 434-439.
- Gurkov R. Clevert D. Krause E. Sonography Versus plain x Ray in diagnosis of nasal fractures

- Am J Rhinol.* 2008; **22**(6): 613-616.
11. Tare Fouad, Mohamed Rifaat, Yasser Madian, Azza Abd Al-Hameed. Utilization Of Ultrasound Imaging For Diagnosis Of Nasal Bone Fracture. *The Egyptian Journal of Ear, Nose, Throat and Allied Sciences(ESENTAS)*, 2009;**10**(2): 54-57.
12. Hyun Sook Hong, Jang Gyu Cha, Sang Hyun Paik, Seong Jin Park, Jai Soung Park, Dae Ho Kim, Hae Kyung Lee. High-Resolution Sonography for Nasal Fracture in Children. *AJR Am J Roentgenol.* 2007;**188**(1):W86-92.