

Hepatocellular study by using long term doses of diclofenac sodium (NSAIDs) in mice models

SARFARAZ H., FARAH K. and N. GANESH

Jawaharlal Cancer Hospital and Research Centre, Idgah hills, Bhopal - 4620 001 (India)

(Received: October 14, 2007; Accepted: November 24, 2007)

ABSTRACT

Diclofenac is a nonsteroidal anti-inflammatory drug (NSAID), which has been associated with severe idiosyncratic hepatotoxicity. In this study we investigated the effects of different doses of diclofenac sodium on liver tissues.

Key words: Non-steroidal anti-inflammatory drug (NSAIDs), Diclofenac sodium, Swiss albino, hepatic cells.

INTRODUCTION

Non-steroidal anti-inflammatory drugs (NSAIDs) are the center piece of pharmacotherapy for most rheumatological disorders and are used in large numbers as analgesics and antipyretics¹⁻⁴. Diclofenac and particularly sulindac are reported to be more commonly associated with hepatotoxicity⁵⁻⁹. Diclofenac sodium causes a rise in liver function, and has also been reported to cause hepatitis¹⁰⁻¹². The exact mechanism is not known but it is probably related to the decrease in the fatty acid entering the cell or released from the cell¹⁶. The literature has continued to broaden our understanding of the potential toxic events associated with the use of these agents¹⁴⁻¹⁵. These products have some potent biological activities affecting cell function in every organ. The high levels of NSAIDs also inhibit the activities of various enzymes, the proteoglycan synthesis from chondrocytes, the ionic exchange rate and the process depending on prostanlandins¹⁴⁻¹⁵. Diclofenac is extremely metabolized in the liver¹⁷. Therefore, the present study aimed to investigate only the hepatotoxic and nephrotoxic effects of increasing doses of diclofenac of liver tissue in mice. Based on several observations, a regular intake of

NSAIDs is associated with a decreased incidence of various type of cancers (Suh O, Mettlin C, *et al.* *Cancer* 1993; 72: 1171-1177) and (Rosenberg L., *et al.*, *J Natl. Cancer Inst.* 1991; 83: 355-358). The experimental results suggest that the toxic effect of diclofenac on hepatocytes may be caused by drug-induced mitochondria impairment, together with a futile consumption of NADPH. (Roque Bort *et al.*) Careful patient monitoring is advised and prompt discontinuation of the drug is suggested when signs or symptoms of liver disease develop (S.M. Helfgott *et al.*) Keeping in view of the previous study done by these above references shown diclofenac caused significantly higher cell death at elevated dose, so we have put our efforts to rule out the toxic menace of diclofenac in rodent's (Swiss albino).

MATERIAL AND METHODS

Swiss albino mice. Age/Weight/Size: 2-3 month's, 30 Grams to 35 Grams-Male and Female both). Diclofenac sodium tablets dissolved in double distilled water in different concentrations for short and long term administration was divided into following groups: (High dose-10mg/Kg for One day only, Medium dose - 1mg/Kg for 10 days only,

Low-0.3mg/Kg for 30 days, Very low-0.1mg/Kg for 30 days, Control-Water without drug). Diclofenac sodium was administered orally with different concentration of drug to separate groups from having 4-animals for each group in, low doses to high dose. Experimental mice were sacrificed by cervical dislocation. The livers were removed, blotted dry on filter paper and weighed. Sections from the left and right lobe of the liver were fixed in 10% buffered formalin for 24 hours, dehydrated in graded

ethanol solutions, embedded in paraffin, sectioned at 5micron and stained with haematoxylin and eosin. The slides were now mounted in DPX.

Observation

Mice were treated with different concentrations of Diclofenac sodium (0.1 mg/kg-10 mg/kg) for different time duration (1 days-30 days), after that they were dissected out, Liver portion was made T.S. and observed under binocular

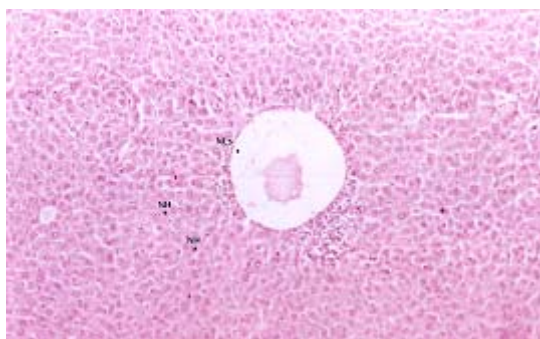


Fig. 1: Histologic section of mice Liver from the control group. Normal lobular structures (NLs), Normal Hepatocytes (NH). (Hematoxylin-eosin, x 100).

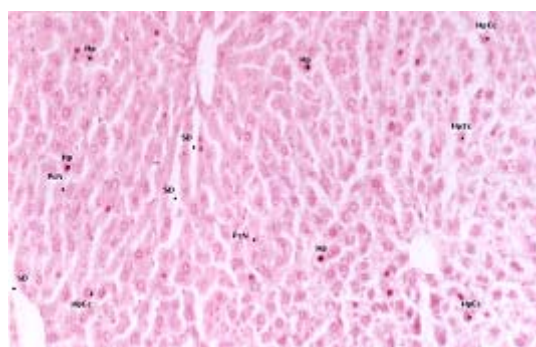


Fig. 2: Histologic section of mice Liver from the (0.1mg/kg) diclofenac sodium administered group. Hypocromic cells (Hp), Hepatocytes with Pyknotic nucleus and Eosinophilic cytoplasm (HpEc) (Hematoxylin-eosin, x 100).

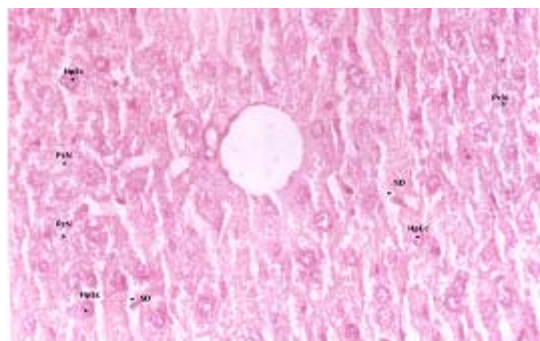


Fig. 3: Histologic section of mice Liver from the (1mg/kg) diclofenac sodium administered group. Parenchymal cell Necrosis (PcN), Sinusoidal dilatations (SD), Hepatocytes with Pyknotic nucleus and Eosinophilic cytoplasm (HpEc) (Hematoxylin-eosin, x 100).

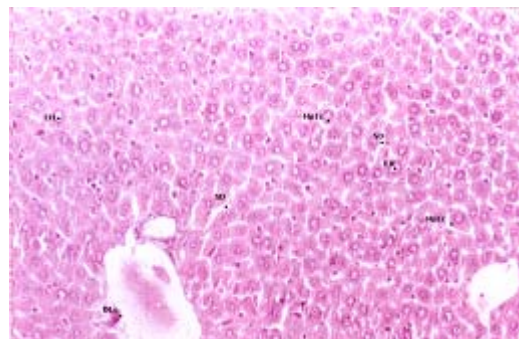


Fig. 4: Histologic section of mice Liver from the (10mg/kg) diclofenac sodium administered group. Sinusoidal dilatations (SD), Hepatocytes with Pyknotic nucleus and Eosinophilic cytoplasm (HpEc), Enlargement in Hepatocytes (EH) (Hematoxylin-eosin, x 100).

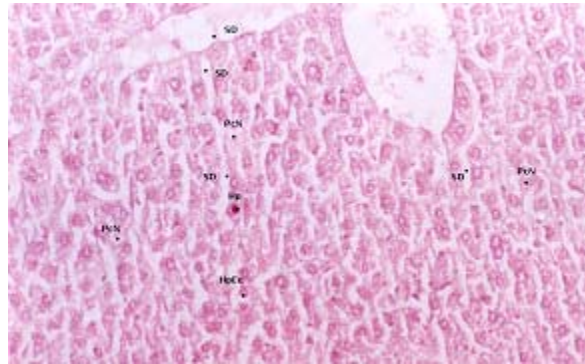


Fig. 5: Histologic section of mice Liver from the (0.3mg/kg) diclofenac sodium administered group. Sinusoidal dilatations (SD), Hypocromic cells (Hp), Parenchymal cell Necrosis (PcN), Hepatocytes with Pyknotic nucleus and Eosinophilic cytoplasm (HpEc), (Hematoxylin-eosin, x 100).

microscope. Histological examination of the liver tissues in the control group revealed no significant dermination from the normal histological structure Fig. 1-5. The Diclofenac sodium treatments groups significantly affected the cellular morphology in the histological structure of the Liver, especially hepatocytes.

RESULTS AND DISCUSSION

In the present study, dose-dependent changes were seen in liver tissue samples. In the first diclofenac group, these changes were very mild and reversible. Similar changes were also seen in

the second diclofenac group. In the third diclofenac group the changes seen compared with those in the first diclofenac group were aggressive and common: there were hepatocyte necrosis. Parenchymal cell Necrosis mild fibrous tissue proliferation and interstitial and periportal inflammation, Hepatocytes with Pyknotic nucleus and Eosinophilic cytoplasm which indicate acute hepatitis. These findings suggest that a high dose of diclofenac sodium causes irreversible cell death, as well as cell damage, fibrous tissue proliferation and acute hepatitis¹²⁻¹³. The association of NSAIDs with liver diseases is poorly documented.

REFERENCES

- Garcia-Rodriguez LA, Williams R, Derby LE et.al Acute liver injury associated with nonsteroidal anti-inflammatory drugs and the role or risk factors. *Arch Int. Med.*, **154**: 311-16 (1994).
- Manoukian AV, Carson JL, Nonsterodial anti-inflammatory drug induced hepatic disorders. Incidence and prevention. *Drug Safety* **15**: 64-71 (1996).
- Walker AM. Quantitative studies of the risk of serious hepatic injury in persons using nonsteroidal anti-inflammatory drug., *Arthritis Rheum.*, **40**: 201-8 (1997).
- Sgro C, Clinard F, Quazir K, *et al.*, Incidence of drug-induced hepatic injuries: a French population-based study. *Hepatology.*, **36**: 451-5 (2002)
- Sheen CL, Dillon JF, Bateman DN, Simpson KJ, MacDonald TM. Paracetamol pack size restriction but the impact on paracetamol poisoning and the over country supply of paracetamol, aspirin and ibuprofen. *Pharmacoepidemol Drug Saf* **11**: 329-31 (2002).
- Dierkes-Globishes A, Schafer R, Mohr HH, Asymptomatic diclofenac-induced acute

- hepatiteis [in German] *Dtsch Med Wochenschr* **125**: 797-800 (2000).
7. Zimmerman HJ. Update on hepatotoxicity due to classes of drugs in common clinical use: non-steroidal drugs, anti-inflammatory drugs, antibiotics, antihypertensives and cardiac and psychotropic agents. *Semi Liver Dis.*, **10**: 322-38 (1990).
 8. Raiobovitz M, Van Thiel DH. Hepatotoxicity of non-steroidal anti-inflammatory drugs. *Am. J. Gastroenterol.*, **87**: 1696-704 (1992).
 9. Bjorkman D. Nonsteroidal anti-inflammatory drug associated toxicity of the liver, lower gastrointestinal tract and the esophagus. *Am J. Med.*, **105**: 17-21S (1998).
 10. Kertz-Rommel, D.A., Boelsteri, U.A., Diclofenac covalent protein binding is dependent on acyl glucuronide formation and is inversely related to P 450-mediated acute cell injury in cultured rat hepatocytes. *Toxicol. Appl. Pharmacol.*, **120**: 155-161 (1993).
 11. Hargus, S.J., amouzedeh, H.R., Pumford, N.R., Metabolic activation and immunochemical localization of liver protein adducts of the nonsteroidal anti-inflammatory drug diclofenac. *Chem. Res. Toxicol.*, **7**: 575-582 (1994).
 12. Tolman, K.G., Hepatotoxicity of non-narcotic analgesics. *Am. J. Med. (Review)*., **105**: 13S-19S (1998).
 13. Histopathologic Changes in Liver and Renal Tissues induced by different doses of diclofenac Sodium in Rats., *Turk J Vet Anim Sci.*, **27**: 1131-1140 (2003).
 14. Skoutakis, V.A., Carter, C.A., Mickle, T.R., Smith, H., Arkin C.R., Alissandrators, J., Petty, D.E., Review of diclofenac and evaluation of its place in therapy as a nonsteroidal anti-inflammatory agents. *Drug. Intell. Clin. Pharm*, **22**: 850-859 (1988).
 15. Kayaalp, S.O., Rasyonel tedavi y.n.nden tobbi framakoloji Medicine Pharamaology. 8. basko. Akara. Hacettepe Taß Kitapcolok, Ltd. pti., 1035-1046 (1998).
 16. Goodman and Gilmanos: Diclofenac sodium. The pharmacological basic of Therapeutics. Ninth Edition. New York p., 637 (1995).
 17. Castel, J.V., Gomez-Lechon, M.J., Ponsoda, X., Bort, R., The use of cultured hepatocytes to nvestigate the mechanism of drug hepatotoxicity. *Cell Biol., Toxicol.*, (Review), **13**: 331-338 (1997).