

Dermatoglyphic Study in Azoospermic and Oligozoospermic Males

Bheem Prasad¹, Padamjeet Panchal¹, and Dayanidhi Kumar²

¹Department of Anatomy, All India Institute of Medical Sciences,
Phulwari Sharif, Patna, Bihar, India.

²Laboratory Director, Indira IVF, Raja Bazaar, Patna, Bihar, India.

<http://dx.doi.org/10.13005/bbra/2880>

(Received: 25 August 2020; accepted: 29 December 2020)

Infertility resulting in men has evoked considerable medical and social interest. The dermatoglyphic study has been proven to be a useful diagnostic tool for different diseases. It is easy due to its cost-effectiveness and non-invasive procedure. Multiple aetiological factors are responsible for azoospermia and oligozoospermia. This study was done to know the dermatoglyphic patterns among male patients suffering from azoospermia and oligozoospermia and compare the findings with the general population. Total seventy-six cases suffering from azoospermia and oligozoospermia were taken with an equal number of individuals in the control group. The fingerprint patterns and ridge counts were compared with healthy age-matched control subjects. The fingerprint patterns were collected by standard ink method. The data was collected and subjected to Chi-square and analysis of variance at a 95 % confidence interval. The overall frequency was loop was higher, followed by whorls and arches in men with azoospermia and oligozoospermia. It was observed that comparing the fingertip ridge patterns and their frequencies were significant ($p < .05$) in azoospermia and oligozoospermia as compared to controls. The increase in the total number of arches was observed in men with oligozoospermia as compared with respect to the control group. The differences in cases and control groups with respect to parameters such as Total finger ridge count (TFRC) as well as Absolute finger ridge count (AFRC) were found statistically insignificant. There is a substantial correlation between fingerprint patterns of men with azoospermia and oligozoospermia males attending the *In Vitro fertilisation* Centre. These correlations may have an essential role in the early diagnosis of reproductive dysfunction in the future.

Keywords: Azoospermia; Dermatoglyphic; Infertility; Oligozoospermia; Patterns; Ridge Count.

Infertility resulting in men has evoked considerable medical and social interest. According to WHO, the infertility is a disease of the reproductive system, defined as the inability to achieve clinical pregnancy over one year or more of regular unprotected sexual intercourse. Male infertility refers to a male's inability to result in pregnancy in a fertile female. Male infertility affects approximately 10% of couples worldwide.¹

Sperm abnormalities have been significantly associated with male infertility. The normal sperm concentration plays a substantial role in fertilisation and pregnancy outcomes.²

The dermatoglyphic study has been proven to be a useful diagnostic tool as a marker for genetic origin diseases. During a few decades, the magnitude of male infertility has increased globally. Early detection of infertility is still

*Corresponding author E-mail: padampanchal@gmail.com



a problematic medical task in such cases. The dermatoglyphic study may play an important role to identify suspected infertile males from a vast population.

An objective of the present study was to investigate dermatoglyphic patterns in azoospermia and oligozoospermia male patients and compare the findings of patients with the general population.

MATERIAL AND METHODS

This study was done on seventy-six infertile males (35 individuals having azoospermia and 41 individuals having oligozoospermia) visiting the Indira *IVF* Centre, Patna, Bihar. The male individuals who have infertility with not less than three years period were included in the infertile group. The average age of included males in the infertile group was 39.84 years. The control group included normal healthy individuals representing the general population having the same reproductive age group and socioeconomic status. The infertile and control subjects without any particular genetic disease were taken. The verbal and informed

consent from individuals of each group were taken. All of them were explained about the procedure of taking dermatoglyphics before having fingerprints and palmar prints.

Clinical information of subjects were collected including age, the period of the marriage, history of infertility and parity. Semen was collected for estimation of sperm count as per the World Health Organization guidelines.³ The individuals of the infertile group were classified based on sperm concentration, as azoospermia (no spermatozoa) and oligozoospermia (<20 million sperm/ml). In the fertile control group, the sperm count was ranged from 35-200 million sperm/ml. The ethical clearance was obtained from the Institutional Ethics Committee, AIIMS, Patna (IEC/AIIMS/PAT/158/2017) before doing this study. Confidentiality and anonymity of subjects were ensured.

Necessary equipment required includes good quality printer ink, a flat glass, rubber roller, glazed surface paper (A3), cotton, turpentine oil, spirit, measuring protractor, sharpener, pointed pencil, and a hand lens (Magnavision).

Table 1. Comparison of Tip ridge pattern of all fingers (both hands) between men with azoospermia and control men

Status	Total number	Loop	Whorls	Arch	Unknown
Azoospermia (35)	350	186 55.14%	104 29.71%	53 15.14%	7 2%
Controls (35)	350	217 62%	96 27.43%	34 9.71%	3 0.86%
Chi ²			8.45		
<i>p</i> value			0.0375*		

*Significant at $p < .05$

Table 2. Comparison of frequencies of different types of fingerprint between men with Oligozoospermia and control men

Status	Total number	Loop	Whorls	Arch	Unknown
Oligozoospermia (41)	410	235 57.32%	122 29.76%	35 8.54%	18 4.39%
Controls (41)	410	259 63.17%	127 30.98%	20 4.88%	4 0.98%
Chi ²			14.27		
<i>p</i> value			0.0026*		

*Significant at $p < .05$

The standard ink method was used to take prints.⁴ The hand was impregnated with a thin layer of ink and gently pressed on the paper from proximal to a distal end. The patterns were classified into loops, whorls, arches and unknown (Galton system).⁵We considered “unknown” to any prints other than these three main classes and their subgroups. The ridges counting of each fingerprint pattern was analysed using a hand lens. The palmar angles such as ‘atd’, ‘dat’ and ‘adt’ were measured after drawing lines connecting the ‘a’, ‘d’ and ‘t’ triradii. The findings of both hands of cases and controls were compared. All data were collected and statistically analysed using the student’s *t*-test and chi-square test. After the sampling data was compiled and analysed in the Department of Anatomy, All India Institute of Medical Sciences, Patna.

RESULTS AND DISCUSSION

The mean age (in years) of cases and control was 39.84±6.02 and 36.30±5.32, respectively. Most of the infertile males were in the age ranging from 41-50 years, comprising approximately 49% of the total cases. Examination on fingerprint patterns revealed that the loop was the most common type of fingerprint, followed by whorls and arches in men with azoospermia and oligozoospermia (53.14% and 57.32% respectively). A statistically significant difference (*p*<.05) was noticed on comparing the fingertip ridge patterns of both hands of azoospermia males and control group. In men with azoospermia demonstrated a higher prevalence of whorl and arch patterns with a low prevalence of loop patterns as compared to the males of the control group (Table 1).

Table 3. Comparison of palmar triradii angle patterns in the right and left hands of cases and controls

Palmar angles	Mean ±SD		<i>p</i> -value	Result
	Cases (n=76)	Controls (n=76)		
	Right Hand			
‘atd’	40.43±5.50	40.84±4.07	0.6041	NS
‘dat’	59.86±5.81	59.20±4.10	0.4213	NS
‘adt’	79.71±5.85	79.96±3.50	0.7498	NS
	Left Hand			
‘atd’	40.47±4.25	41.61±4.26	0.1033	NS
‘dat’	59.53±5.88	57.84±4.39	0.0473*	S
‘adt’	80.00±5.32	80.55±3.84	0.4637	NS

*S: Significant at *p*<.05, †NS: Not significant

Table 4. Finger ridge count (TFRC and AFRC) observed in men with azoospermia and oligozoospermia

Parameter	TFRC		AFRC	
	N	Mean	N	Mean
Azoospermia	4496	128.45	6152	177.77
Oligozoospermia	5498	134.10	7212	134.10
<i>t</i> value	0.5936		0.0077	
<i>p</i> value	0.5546		0.9939	
Result	NS		NS	

NS: Not statistically significant

Similarly, on observing the frequencies of different types of fingertip patterns in men with oligozoospermia and control males, we also found the statistically significant differences in these groups ($p < .05$). The total number of arches was increased in men with oligozoospermia (35; 8.54%) as compared to control males (20; 4.88%) (Table 2). The mean of 'dat' angle (left hand) of cases (azoospermia and oligozoospermia) was statistically significant on comparing with the control group. In contrast, the other angles, such as 'atd' and 'adt' palmar angles were found

insignificant in both hands of infertile and control groups (Table 3).

The observed mean TFRC (Total finger ridge count) seen between azoospermia and oligozoospermia infertile males was 128.45 and 134.10, respectively, whereas mean AFRC in those two groups was 177.77 and 134.10, respectively. There were insignificant differences between both types of infertile males concerning AFRC and TFRC (Table 4).

In the present study, most of the infertile males were between the age group of 41-50

Finger tip patterns between men with azoospermia and control

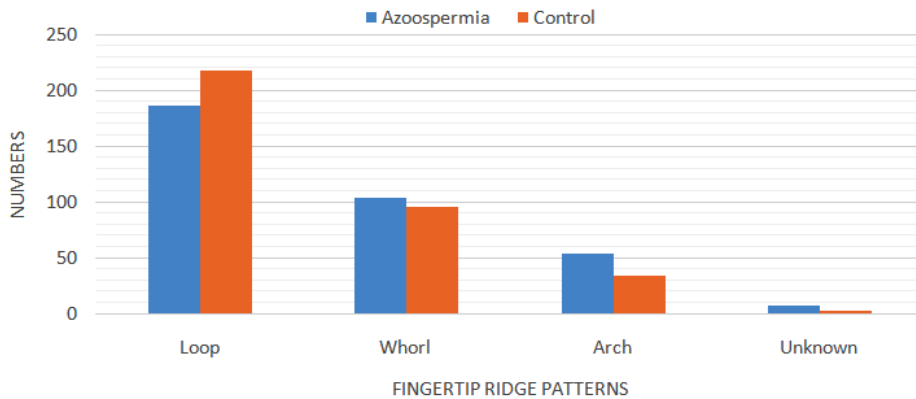


Fig. 1. Showing the frequency distribution of fingerprint patterns in men with azoospermia and controls

Finger tip patterns between men with oligozoospermia and controls

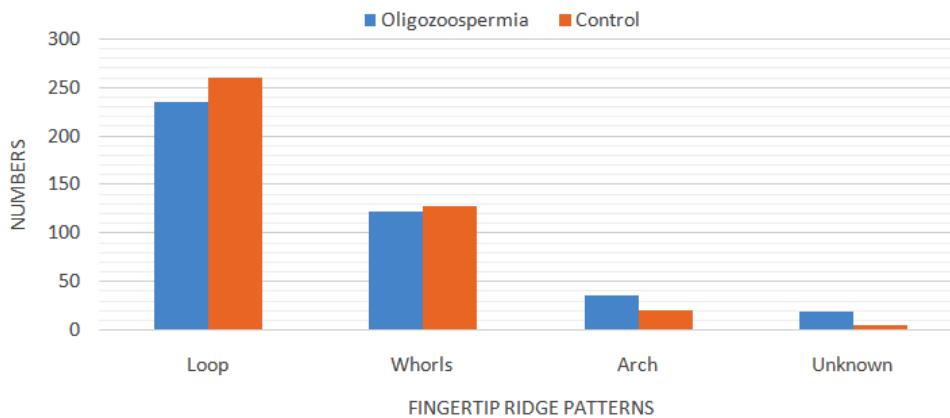


Fig. 2. Frequency distribution of fingerprint patterns in men with oligozoospermia and controls.

(37; 48.68%). Some studies suggested that the advanced age may be associated with impaired sexual function, sperm count profile which may be responsible for increased time to conception, and increased miscarriage rates.⁶⁻⁸ The main concern of this work was to compare the dermatoglyphic patterns in infertile men with azoospermia and oligozoospermia. Based on the result, the most common type of fingerprints in these cases was a loop pattern. Statistically significant differences were found in fingerprint patterns of cases and controls. A significant decrease in the frequency of loops in men with azoospermia (186, 55.14%) and oligozoospermia (255, 57.32%). Whereas in controls the frequency of loops (217, 57.32% and 259, 63.17% respectively). Similar results were also reflected in a dermatoglyphic study conducted on 24 infertile males by Sontakke *et al.*⁹ While Makol *et al.*¹⁰ in New Delhi and Jafari *et al.*¹¹ in Iran found significantly increased frequencies of loops in infertile males as compared to that of controls. The increased whorl pattern in the infertile men with azoospermia (104, 29.71%) as compared to that of controls (96, 27.43%). A similar finding was reached by Sontakke *et al.*⁹ and Jafari *et al.*¹¹, but this outcome is contrary to that of Singh *et al.* (2017) who found that in infertile males, there was a significant decrease in the frequency of whorls as compared to the general population.¹³

We found a significantly increased frequency of arches in men with azoospermia (53, 15.14%) and oligozoospermia (35, 8.54%) as compared to controls (34, 9.71% and 20, 4.88% respectively). The arches increased frequency was consistent with the findings of Sontakke *et al.*⁹ and Prasad *et al.*¹² In another study done on infertile males and compared to controls by Singh *et al.* reported significantly decreased frequencies in the arches.¹³

The present study has shown that the significant differences in 'atd' angle (left hand) among infertile males and control group, whereas the findings of the right hand were insignificant regarding differences in 'atd' angle among infertile males and control group. Partial similar findings were reported by Sontakke *et al.*⁹ and Prasad *et al.*¹²

The finger ridge count determines the size of the pattern. In this study, we found that differences in men with azoospermia and

oligozoospermia concerning TFRC and as well as AFRC were insignificant. Similarly, on comparing with the control, non-significant differences in TFRC and AFRC of infertile patients were reported by Sontakke and colleagues as well as also by Jafari *et al.* Singh *et al.* also reported similar facts in oligozoospermia affected males.^{9,11,13}

CONCLUSIONS

The dermatoglyphic study is easy due to its cost-effectiveness and non-invasive procedure and would serve as a prediction tool, for early screening of infertile male subjects. This study revealed a significant dermatoglyphic difference between controls and men with azoospermia and oligozoospermia. This study showed an increased number of whorl and arch patterns along with decrease number of loop patterns with an increase in the 'dat' angle value of the left hand. The detection of such patterns by a physician could aid them to anticipate infertility problems in the susceptible patient. It can be used as a ready cost-effective screener to identify infertile subjects from a larger population for further investigations and to confirm or rule out infertility in such patients. So, physicians may advise for necessary preventive and encouraging health measures for individuals at risk.

ACKNOWLEDGEMENTS

Authors are very thankful to Dr Dayanidhi Kumar, who gave us the chance to get the fingerprints of infertile males in Indira IVF, Patna, Bihar. We are also grateful to the persons who have extended their cooperation in this study.

Conflict of Interest

None.

Financial support and sponsorship

It was a non-funds project-based work. No financial support or any sponsorship was taken by any of the authors for the same.

REFERENCES

1. Prasad B, Jain R. The Cytogenetic Basis of Human Infertility: A Review. *Journal of Dental and Medical Sciences*. 2014; **13**(8):83-88. <http://www.iosrjournals.org/iosr-jdms/papers/Vol13-issue8/Version-2/Q013828388.pdf> DOI:

- 10.9790/0853-13828388
2. Bonde JP, Ernst E, Jensen TK, Hjollund NH, Kolstad H, Henriksen TB et al. Relation between semen quality and fertility: a population-based study of 430 first-pregnancy planners. *Lancet*. 1998; 352:1172-1177. [https://www.thelancet.com/journals/lancet/article/PIIS0140-6736\(97\)10514-1/fulltext](https://www.thelancet.com/journals/lancet/article/PIIS0140-6736(97)10514-1/fulltext) DOI: 10.1016/S0140-6736(97)10514-1 PMID:9777833
 3. Cooper TG, Noonan E, von Eckardstein S, Auger J, Baker HW, Behre HM, Haugen TB, Kruger T, Wang C, Mbizvo MT, Vogelsong KM. World Health Organization reference values for human semen characteristics. *Hum Reprod Update*. 2010 May-Jun; **16**(3):231-45. <https://academic.oup.com/humupd/article/16/3/231/639175> DOI:10.1093/humupd/dmp048. PMID:19934213.
 4. Cummins H, Mildo C, editors. Methods of printing ink method. Fingerprints of Palms and Soles: In: *An Introduction to Dermatoglyphics*. 1st ed. Philadelphia, PA: Blakiston Company; 1943. p. 45-55.
 5. Galton F. *Finger prints*. Facsimile Ed. New York and London: Mac Millan; 1892.
 6. Ford WC, North K, Taylor H, Farrow A, Hull MG, Golding J. Increasing paternal age is associated with delayed conception in a large population of fertile couples: evidence for declining fecundity in older men. The ALSPAC Study Team (Avon Longitudinal Study of Pregnancy and Childhood). *Hum Reprod*. 2000; **15**(8):1703-8. <https://academic.oup.com/humrep/article/15/8/1703/670811> DOI: 10.1093/humrep/15.8.1703. PMID:10920089.
 7. Hassan MA, Killick SR. Effect of male age on fertility: evidence for the decline in male fertility with increasing age. *Fertil Steril*. 2003; **79**(3):1520-7. [https://www.fertstert.org/article/S0015-0282\(03\)00366-2/pdf](https://www.fertstert.org/article/S0015-0282(03)00366-2/pdf) DOI: 10.1016/s0015-0282(03)00366-2. PMID:12801554.
 8. Elzanaty S. Association between age and epididymal and accessory sex gland function and their relation to sperm motility. *Arch Androl*. 2007; **53**(3):149-56. <https://pubmed.ncbi.nlm.nih.gov/17612873/> DOI: 10.1080/01485010701225667. PMID:17612873.
 9. Sontakke BR, Talhar S, Ingole IV, Shende MR, Pal AK, Bhattacharaya T. Dermatoglyphic pattern in male infertility. *Nepal Med Coll J*. 2013; **15**(2):106-9. <https://pubmed.ncbi.nlm.nih.gov/24696927/> PMID:24696927.
 10. Makol N, Kshatriya G, Basu S. Study of finger and palmar dermatoglyphics in primary infertile males. *Anthropol Anz*. 1994; **52**(1):59-65. <https://pubmed.ncbi.nlm.nih.gov/8192434/> PMID:8192434
 11. Jafari HP, Chaleshtori MH, Farhud DD. Dermatoglyphics in Patients with Oligo / Azoospermia. *Iranian J Publ Health*. 2005; **34**: 56-61. <https://ijph.tums.ac.ir/index.php/IJPH/article/view/1856>
 12. Prasad B, Kumari S, Panchal P, Kumar D. Palmar and digital dermatoglyphic patterns in infertile males in the population of Bihar. *Med. Res. Chron*. 2018; **5**(5):323-329. <https://medrech.com/index.php/medrech/article/view/320> DOI:10.26838/medrech.2018.5.5.429
 13. Singh B, Jafar S. Study of Fingerprint Patterns in oligospermic Male. *Journal of Medical Science and Clinical Research*. 2017; 05(11): 30480-83. <http://jmscr.igmpublication.org/v5-i11/113%20jmscr.pdf> DOI:<https://dx.doi.org/10.18535/jmscr/v5i11.113>