

Infected Parotid Cyst- A Case Report with Review of Literature

V. Aarthi Nisha¹, J. Parthiban², T. Manigandan³,
A. Amudhan⁴ and B. Saravanakumar⁵

^{1,3-4}Department of Oral Medicine And Radiology, Sree Balaji Dental
College and Hospital, Bharath University. Chennai, India.

²Department of Oral And Maxillofacial Surgery, Tagore Dental College and Hospital, Chennai, India.

⁵Department of Oral And Maxillofacial Surgery, Sree Balaji Dental College And Hospital,
Bharath University. Chennai, India.

dx.doi.org/10.13005/bbra/1248

(Received: 10 January 2014; accepted: 05 February 2014)

A 45 year old female with complain of soft fluctuant swelling of the left parotid region. The lesion was found to be cystic when preoperative examinations were performed. This was again confirmed by ultrasonography of the parotid gland and Fine needle aspiration biopsy (FNA). Hence in this paper we report a case of infected parotid cyst and the diagnosis, investigations and treatment plan which are elaborated.

Key words: Parotid Cyst, Ultrasonography, Rotated PA, FNAB.

Cystic lesions of the parotid gland are uncommon and it comprises approximately 5% of all salivary gland tumors. Cysts of the salivary glands may originate as benign non-neoplastic entities or in association with benign and malignant tumors of the salivary glands. Cystic development as part of specific neoplasms of the salivary glands is well recognized, including those that occur in the pleomorphic adenoma, Warthin's tumor, mucoepidermoid carcinoma, acinic cell carcinoma, and the adenoid cystic carcinoma². The histologic features of these neoplasms are sufficiently distinctive; however, non-neoplastic salivary gland cysts do require differentiation from cystadenoma, mucoepidermoid carcinoma, and acinic carcinoma. Many cysts of the salivary glands may be generically attributed to an obstructive process². They can occur as a result of traumatic severance of

salivary gland ducts, partial or complete blockage of the excretory ducts, or stasis of salivary flow in ducts. Many of them represent cystic components of neoplasm. In most cases, the appearance of these cysts on computed tomography (CT) or magnetic resonance imaging (MRI) is not specific enough to allow the differentiation of a simple parotid cyst from a brachial cleft cyst³. Patients most commonly present in the fifth decade and although duct obstruction appears to be the cause, the source of the obstruction is often not apparent. Most lesions are slowly enlarging painless swellings affecting a single gland⁴. Hence, the diagnosis is seldom made preoperatively and sometimes a superficial parotidectomy is needed⁵.

Case report

A 45 year old female reported with a chief complaint of stains on her teeth and wanted to get it cleaned. On examination extraorally, a solitary, well-defined, round mass, 2X1.5cm, on the left side pre auricular region, extending from the anterior border of the masseter muscle to the tragus of ear was present (fig 1). The patient had noticed the swelling but she ignored it as she was

* To whom all correspondence should be addressed.
Mob.: +91-9500027640; +91-9443529399.
E-mail id: drnishaparthi@gmail.com

asymptomatic. But she reported it to be enlarging in size. The skin over the lesion appeared to be stretched. On palpation, the consistency of the mass was elastic firm and was non tender in nature. The swelling becomes more prominent on clenching the teeth. Intraoral examination of the left stenson's duct opening on the buccal mucosa appeared to be normal. A provisional diagnosis of benign tumor of parotid gland was arrived. The patient was subjected to various investigations such as conventional radiography, ultrasonography and fine needle aspiration biopsy (FNA). Radiographs such as rotated postero-anterior (PA) view and soft tissue radiograph of the left cheek were taken. Both the rotated postero-anterior (PA) view revealed a radiopaque oval mass below the zygomatic arch connected to a radiopaque stalk (fig2&3). Ultrasonography

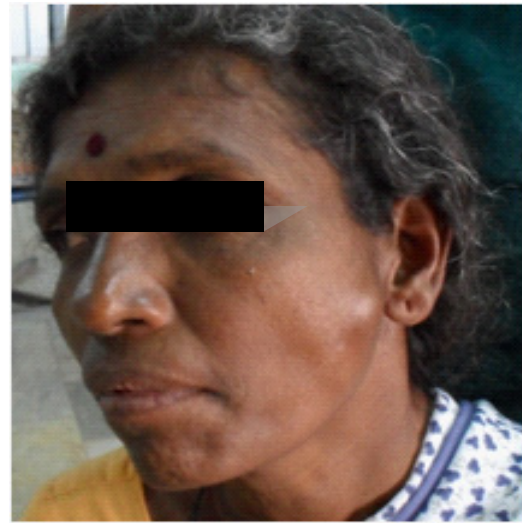

Fig. 1. Swelling over left parotid region

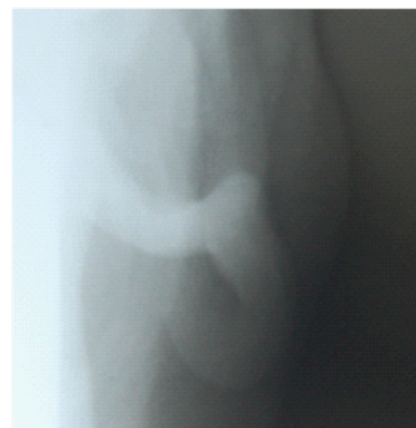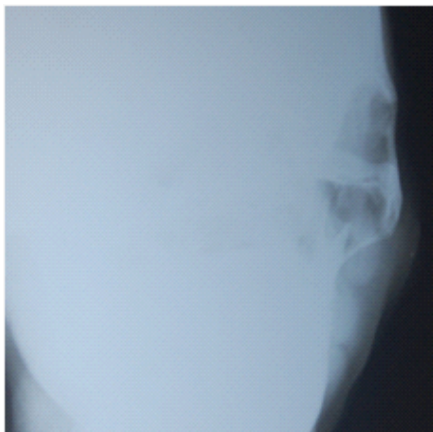


Fig. 2-3. Rotated PA view and soft tissue cheek revealed a radiopaque oval mass below the zygomatic arch connected to a radiopaque stalk

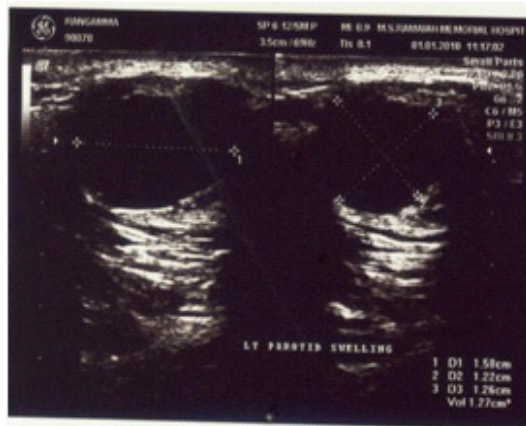


Fig. 4. USG revealed a well defined hypoechoic area with posterior enhancement within the left parotid gland

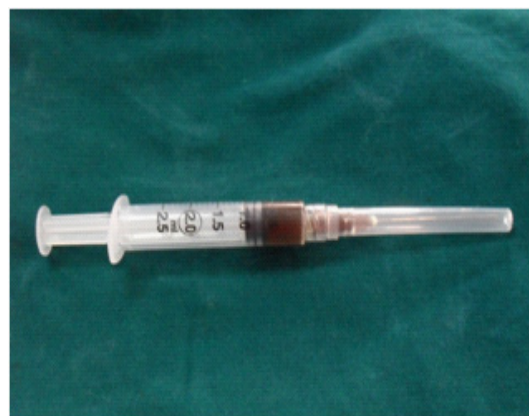

Fig. 5. FNA revealing chocolate brown, hemorrhagic aspirate

revealed a well defined hypoechoic area with posterior enhancement within the left parotid gland suggestive of cystic swelling. The lesion was measuring about 1.58cmX1.22cm in its greatest dimension (fig 4). Fine needle aspiration of the mass yielded a chocolate brown, hemorrhagic fluid (fig 5) which on cytological examination revealed sparsely cellular smear consisting of inflammatory infiltrate predominantly with neutrophils, lymphocytes and cyst macrophages against a proteinaceous background suggestive of an infected cyst of the left parotid gland. The patient was not willing to undergo further investigations such as MRI as she was apprehensive and she even refused for the treatment of the swelling. So based on clinical presentation, aspiration and ultrasound a final diagnosis of infected cyst of the left parotid gland was given.

DISCUSSION

Intraparotid cystic swellings are uncommon. The main types of parotid cyst that can be found in the parotid gland are: 1) simple cysts, compared with both the extravasation and retention type of mucocele, but larger; 2) lymphoepithelial cysts, which are mainly congenital, but also reported in AIDS patients; 3) a polycystic disease of the parotid gland, a developmental disorder which is seen bilaterally especially in females; 4) cystic tumors⁶. A review of 100 cases, found parotid cyst to be commonest non- neoplastic disease (10%). Histologically 7 were simple cysts and 2 were lymphoepithelial cysts⁷. The clinical diagnosis of parotid cyst is often based on a slowly enlarging painless lump in the parotid region, the examination not always confirming the cystic nature of the lesion. Investigations are important for diagnosis and treatment planning of these lesions. Fine needle aspiration biopsy (FNA) is useful in certain cases⁸. Ultrasound is useful in showing cystic nature of the lesion. CT and MRI provides clear image of the lesion and reveal intraparotid cystic masses⁹. Management of such lesions should be superficial

parotidectomy when a conservative approach cannot safely remove the lesion¹⁰.

CONCLUSION

Although intraparotid cystic masses are uncommon, we should be able to distinguish it from the benign tumors of the parotid gland as it may greatly affect the treatment plan. Thorough clinical examination, appropriate investigations and diagnosis will assist in planning the treatment.

REFERENCES

1. K Altman, B.M.W.Bailey: Parotid cyst: A case report. *Int.J.Oral Maxillofac Surg*. 1994; **23**:165-66.
2. Dardick I. 1996. Mucocele and sialocysts. In: Color Atlas Text of Salivary Gland Tumor Pathology. New York: Igaku-Shoin Medical Publishers, pp. 131-141.
3. Hironori Akiyam, Junko Tamaki, Hiroaki Shimamoto, Toshihide Nakamura. First brachial cleft cyst in the parotid area. *Oral Radiol*. 2006; **22**: 89-92.
4. Batsakis J.G. and Raymond A.K. Sialocysts of the parotid glands. *Annals of Otolaryngology and Laryngology*. 1989; **98**: 487-489.
5. S. Rahman, R.Shaari, R. Hassan. Parotid Lymphoepithelial Cyst: A Case Report. *Archives of Orofacial Sciences* 2006; **1**: 71-75.
6. Holliday RA, Cohen WA, Schinella RA. Benign lymphoepithelial parotid cyst and hyperplastic cervical lymphadenopathy in AIDS risk patients: A new CT appearance. *Radiology*. 1988; **168**: 439-41.
7. Adekeye EO, Ord RA. Surgical parotid disease in Nigeria: a review of 100 cases. *J Maxillofac Surg*. 1984; **12**:118-22.
8. Droese M. Cytological diagnosis of sialadenitis, sialadenitis, and parotid cysts by fine needle aspiration biopsy. *Adv Otorhinolaryngol* 1981; **26**: 49-96.
9. Wardbooth RP, Williams ED, Faulkner TP, Earl PD. Ultrasound : a simple non invasive examination of cervical swellings. *Plast Reconstr Surg*. 1984; **73**: 577-81.
10. Maynard JD. Solitary cysts of the parotid. *Br J Surg*. 1988; **75**(10): 1043.