

## Implant Imaging - A Literature Review

**N. Manisundar, B. Saravanakumar. V.T. Hemalatha,  
T. Manigandan and A. Amudhan**

Department of Periodontics , Sree Balaji Dental College & Hospital,  
Bharath University, Chennai, Tamil Nadu, India.

[dx.doi.org/10.13005/bbra/1251](https://doi.org/10.13005/bbra/1251)

(Received: 10 January 2014; accepted: 05 February 2014)

Dental implants have become an accepted form of permanent tooth replacement. Nearly all implants currently being placed are of the osseointegrated type. These typically consist of three parts: a fixture, an abutment, and a screw or threaded rod. The fixture, usually composed of titanium, can be placed in either a surgically created site in the alveolar ridge or a fresh extraction socket. Diagnostic imaging can play an important role in evaluating patients with such implants. Useful imaging studies include plain panoramic radiography, computed tomography, and computer-reformatted cross-sectional, panoramic, and three-dimensional imaging. Advanced imaging studies can be used to determine the suitability of implant placement, appropriate sites for implant placement, the size of the implant that can be placed, and the need for preimplantation ridge surgery. The intent of this article is to provide an overview of the diagnostic role of the dental implant imaging.

**Key words:** Osseointegrated, fixture, endosseous implant.

---

Dental implants are used to replace both the form and the function of missing teeth. The use of dental implants for replacing missing teeth and other oral structures has been increasing rapidly throughout the world, with functional 5-year success rates of 90% or higher reported. There are a number of basic principles of radiography that should guide the clinician in selecting an appropriate imaging technique and judging whether the resultant images are of adequate quality for the purpose. The choice of radiologic technique appropriate for a given patient depends on a number of factors, including the type of implant to be used, the position of the remaining dentition

and the extent to which bone quality or quantity is in question. Maximizing the ratio of the benefit/risk for imaging examinations is a fundamental tenet of radiology. These imaging modalities can be described as either analog or digital and two-dimensional or three-dimensional.<sup>1</sup>

The actual dental implant is a metal screw designed to thread into the jawbone and allow for the attachment of a variety of prosthetic dental replacements. Most of the time, the implant is made of medical grade titanium or a titanium alloy. Titanium is used due to its excellent compatibility with human biology. Although we have a number of restorative options for the treatment of missing teeth, none have proven to be as functionally effective and durable as implants. In many cases, dental implants may be the only logical choice for the restoration of all necessary functionality of the teeth and supporting structures. In short, dental implants serve some important functions like

---

\* To whom all correspondence should be addressed.  
Mob.: +91-9943932757;  
E-mail: [drmanisundarmds@gmail.com](mailto:drmanisundarmds@gmail.com)

- 1) To replace a single or multiple teeth without affecting adjacent teeth
- 2) To support bridgework or replace a partial denture
- 4) To help support or secure upper or lower dentures
- 5) To help as an anchorage
- 6) To help and support in orthodontic treatment

Under the right conditions and with the appropriate maintenance dental implants can last a lifetime. Ongoing long-term studies show that dental implant treatments generally exhibit predictable and excellent success rates.<sup>2</sup>

#### **Basic principles to follow during implant imaging**

The AAOMR recommends that the dentist or radiologist be closely involved in office implant imaging and that the task not be delegated completely to auxiliaries. The dentist or radiologist should complete the following steps in conducting a conventional tomographic implant imaging examination: (1) take an appropriate scout film (panoramic or occlusal, depending on the tomographic equipment) to aid in selecting imaging planes and angles; (2) verify implant sites by using stents with radiopaque indicators, preferably based on diagnostic wax-ups; (3) use beam-indicating lights and cephalostat as appropriate for the specific equipment; (4) orient the cross sectional images perpendicular to the desired region of the jawbone; (5) obtain longitudinal or para sagittal images along with the cross-sectional images so that cross correlation is possible; and (6) write a complete report with tracings, measurements, or both for each patient. For CT imaging, the referring dentist should communicate thoroughly with the radiologist (medical or oral and maxillofacial) and ensure that the patient is positioned appropriately (0 degree gantry angle), that a stent with radiopaque markers (gutta percha) is used, and that the scan plane is parallel to the occlusal plane.<sup>3</sup>

Imaging objectives:

#### **Implant imaging consists of 3 phases**

- 1) Phase I is termed presurgical implant imaging
- 2) Phase II is termed surgical and intraoperative implant imaging
- 3) Phase III is termed postprosthetic implant imaging

An important aspect of radiographic evaluation should be a qualitative description of the bone in the target area. The most favorable osseointegration is thought to occur only in certain types of bone. Although there is no single universally accepted system for classifying bone quality in the maxilla and mandible, the Misch system based on the radiographic appearance of bone has been widely used by clinicians.<sup>4</sup>

#### **The Misch system divides bone into 4 subdivisions**

The Misch system is widely used by clinicians and divides bone into four subdivisions based on the observed bone density (D-1 to D-4); D-1 and D-2 bones generally have dense cortical plates with coarse trabeculae and small bone marrow spaces, D-1 (atrophic anterior mandible) being denser than D-2 (anterior maxilla, anterior and posterior mandible). D-3 (anterior and posterior maxilla) and D-4 (posterior maxilla) bones range from poorly mineralized or thin trabeculae to complete paucity of mineralized trabeculae (D-3 being denser than D-4).<sup>4</sup>

The risk from dental radiology may be the lowest in medical radiology; however, the risk from maxillofacial radiology is comparable to the risk from conventional exposures in general radiology. For this reason, a classification is proposed regarding when to perform cross-sectional imaging.<sup>5</sup>

- |         |   |
|---------|---|
| Class 1 | Anterior segments in the maxilla (from canine to canine)  |
| Class 2 | Posterior segments distal to the canines in the maxilla   |
| Class 3 | Anterior segments in the mandible (from canine to canine) |
| Class 4 | Posterior segments distal to the canines in the mandible  |

#### **Diagnostic imaging modalities**

##### **Periapical Radiography (figure 1)**

Periapical radiographs produce a high resolution planar image. Periapical radiographs may suffer from both distortion and magnification which is limited by using long cone paralleling technique.<sup>6</sup> In terms of the objectives of preprosthetic imaging, periapical radiography is:

1. A useful for ruling out local bone or dental disease.
2. Of limited value in determining quantity because the image is magnified, may be

Classification of When to Perform Cross-Sectional Imaging in Implant Dentistry<sup>5</sup>

Region	Indications	Optimal indications
I. Anterior segments in the maxilla (areas from canine to canine)	Severe bone loss with enlarged incisor canal for single implants in the incisor region or multiple implants in the incisor and canine regions	Bone volume impossible to assess by means of clinical examination because of unfavorable soft tissue conditions
II: Posterior segments distal to the canines in the maxilla	Severe bone loss and close proximity of the maxillary sinus For a fixed prosthesis in the Completely edentulous maxilla	Bone volume impossible to assess by means of clinical examination because of unfavorable soft tissue conditions
III: Anterior segments in the mandible (areas from canine to canine)	For a fixed prosthesis in the completely edentulous mandible	Bone volume impossible to assess by means of clinical examination because of unfavorable soft tissue conditions For interforaminal implantation in case of atrophy corresponding to Cawood and Howell level V and VI
IV: Posterior segments distal to the canines in the mandible	For a fixed prosthesis in the completely edentulous mandible	Bone volume impossible to assess by means of clinical examination because of unfavorable soft tissue conditions In cases of a pronounced mylohyoid line submandibular fossa or other distinct anatomic undercut

3. distorted, and does not depict the third dimension of bone width.
4. Of limited value in determining bone density or mineralization.
5. Of value in identifying critical structures, but of limited value in depicting the spatial relationship between the structures and the proposed implant site.
6. Most often used for single tooth implants in regions of abundant bone width.

**Occlusal Radiography (figure 2)**

Occlusal radiographs are planar radiographs. Occlusal radiography produces high resolution images. Produces an oblique and distorted image of the mandibular and maxilla, which is of little use. In addition, it shows the widest width of bone vs the width at the crest, where diagnostic information is needed most. The degree of mineralization of trabecular bone can be not determined, and the spatial relationship between

the critical structures and the proposed implant site is lost. Although helpful, these views are two dimensional. The standard Occlusal film provides generalized information about bone density and the width of the inferior border of the mandible; laterally exposed film shows the width of the bone in the midline.<sup>6</sup> As a result, Occlusal radiographs rarely indicated for diagnostic preprosthetic phases in implant dentistry.<sup>7</sup>

**Panoramic Radiography**

Panoramic radiography is a curved plane tomographic radiographic technique used to depict the body of the mandible, maxilla, and the lower one half of the maxillary sinuses in a single image. This is the most utilized diagnostic modality in implant dentistry.<sup>11</sup> This radiographic technique produces an image of a section of the jaws of variable thickness and magnification. Panoramic images offer the following advantages:

1. Opposing landmarks are easily identified.

Summary of selection of imaging modality<sup>22</sup>

Imaging modality	Applications	Cross-sectional information	Advantages	Disadvantages	Radiation dose
Periapical Radiography	S,M,E,A	No	<ul style="list-style-type: none"> <li>• Readily available</li> <li>• High resolution</li> <li>• Low cost</li> <li>• minimal distortion</li> <li>• Readily available</li> </ul>	<ul style="list-style-type: none"> <li>• limited imaging area</li> <li>• no facial-lingual dimension</li> <li>• limited reproducibility</li> <li>• image elongation or foreshortening</li> <li>• No detailed facial-lingual</li> <li>• High image definition</li> <li>• Limited reproducibility</li> <li>• Not as applicable for maxilla</li> <li>• Image superimposition</li> </ul>	Low
Occlusal	S,M,A	No	<ul style="list-style-type: none"> <li>• Gross Facial-lingual dimension</li> <li>• Relatively large imaging area</li> <li>• Low cost</li> </ul>		radiography Low dimension
Panoramic radiography	S,M,E,A	No	<ul style="list-style-type: none"> <li>• Readily available</li> <li>• Large imaging area</li> <li>• Minimal cost</li> </ul>	<ul style="list-style-type: none"> <li>• No detailed facial-lingual dimension</li> <li>• Image distortion</li> <li>• Technique errors are common</li> <li>• Inconsistent magnification</li> <li>• Geometric distortion</li> </ul>	Low
Conventional tomography	S,M,E,A	Yes	<ul style="list-style-type: none"> <li>• Minimal superimposition</li> <li>• Facial-lingual dimension</li> <li>• Uniform magnification</li> <li>• Accurate measurements</li> <li>• Moderate cost</li> <li>• Simulates placement with software</li> </ul>	<ul style="list-style-type: none"> <li>• Less image definition than plain films</li> <li>• somewhat limited availability</li> <li>• special training for interpretation</li> <li>• sensitive to technique errors</li> </ul>	Moderately low, depends on sites
Reformatted Computed tomography	M,E,A	Yes	<ul style="list-style-type: none"> <li>• allows evaluation of all possible sites</li> <li>• no superimposition</li> <li>• uniform magnification</li> <li>• Accurate measurements</li> <li>• Simulates placement with software</li> </ul>	<ul style="list-style-type: none"> <li>• Limited availability</li> <li>• sensitive to technique errors</li> <li>• metallic image artifacts</li> <li>• special training for interpretation</li> <li>• High cost</li> </ul>	High

S- single implant, M- multiple implants , E- edentulous, A- augmentation

2. Vertical height of bone initially can be assessed.
3. Can be performed with convenience, ease and speed.
4. Gross anatomy of the jaws and any related pathologic findings can be evaluated.

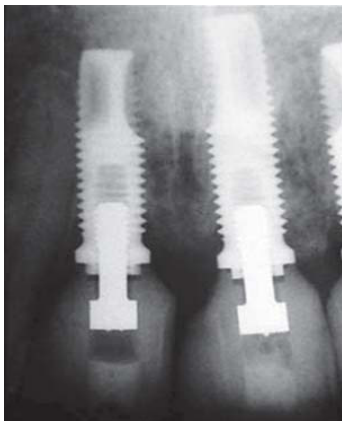
#### **Shortcomings of Panoramic Imaging**

1. Does not demonstrate bone quality/mineralization.
2. Misleading quantitatively because of magnification and because the third dimension, cross sectional view is not demonstrated.
3. Of some use in demonstrating critical structures but of little use in depicting the spatial relationships between the structures and dimensional quantification of the implant site shows 10% magnification.

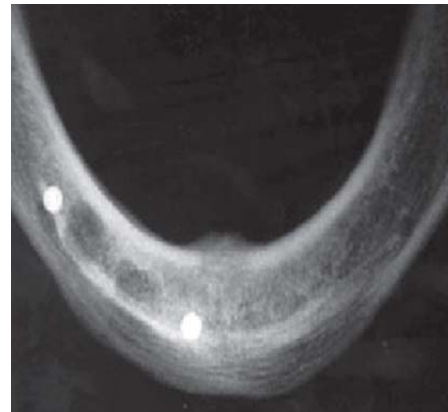
#### **Cephalometric Radiographs (Fig.4,5)**

Cephalometric radiographs are oriented

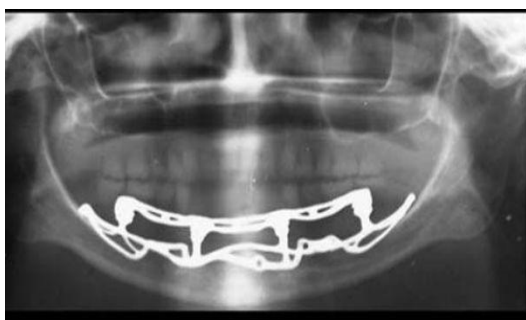
planar radiographs of the skull. The skull is oriented to the x-ray device and the image receptor using a cephalometer, which physically fixes the position of the skull with projections into the external auditory canal. The geometry of cephalometric imaging devices results in a 10% magnification of the image with a 60-inch focal object and a 6-inch object-to-film distance.<sup>8</sup> A lateral cephalometric radiograph is produced with the patient's midsagittal plane oriented parallel to the image receptor. This radiograph demonstrates a cross-sectional image of the alveolus of the mandible and the maxilla in the midsagittal plane. With a slight rotation of the cephalometer, a cross-sectional image of the mandible or maxilla can be demonstrated in the lateral incisor or in the canine regions. Unlike panoramic or periapical images, the cross-sectional view of the alveolus demonstrates the spatial relationship between occlusion and esthetics with the length, width, angulations, and



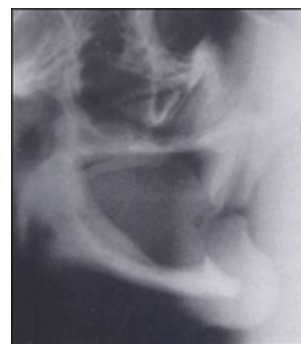**Fig. 1.** Periapical radiographs: Implants 11, 21, 22, screw-retained ceramic abutments



**Fig. 2.** Occlusal radiograph showing surgical guide

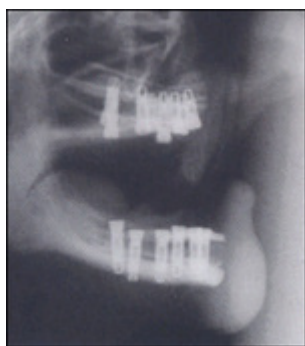

**Fig. 3.** Panoramic radiograph demonstrating a mandibular subperiosteal implant

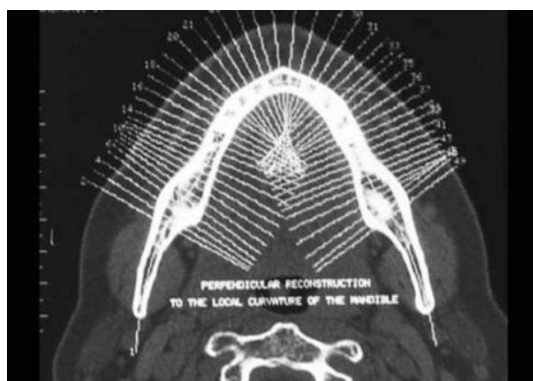


**Fig. 4.** Cephalometric radiograph before placing

The inter alveolar distance and the amount of available bone are evaluated pre surgically using standard lateral cephalometric films as well as mounted study models.



**Fig. 5.** Cephalometric radiograph after placing implant

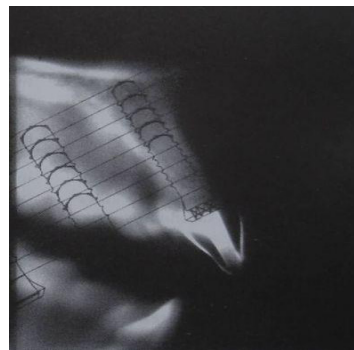


**Fig. 7.** Axial CT view of the mandible showing the potential crosssectional slices that can be reformatted by Dentascanner

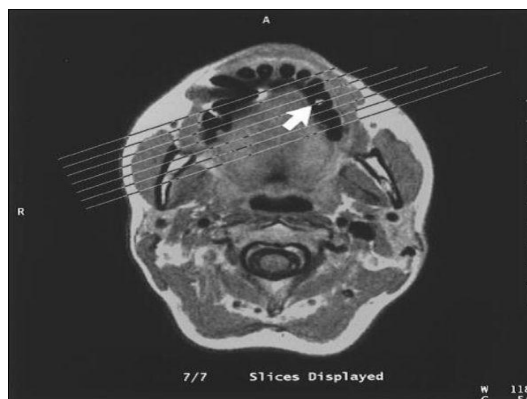
geometry of the alveolus and is more accurate for bone quantity determinations. Implants often must be positioned in the anterior regions adjacent to the lingual plate.<sup>9</sup>

The lateral cephalometric radiograph is useful because it demonstrates the geometry of the alveolus in the mid-anterior region and the relationship of the lingual plate to the patient's skeletal anatomy. The width of bone in the symphysis region and the relationship between the buccal cortex and the roots of the anterior teeth also may be determined before harvesting this bone for ridge augmentation. Together with regional periapical radiographs, quantitative spatial information is available to demonstrate the

Lateral cephalometric radiograph after ridge augmentation and implant placement. The reduction in ridge-to-ridge distance that accompanies ridge augmentation leads to most favorable conditions for a functionally and esthetically satisfactory prosthetic result.



**Fig. 6.** Conventional tomogram showing clear plastic overlay used to visualize and determine desired length of implant placement



**Fig. 8.** A transaxial image showing the marker indicating the potential implant site (arrow). The lines show the planned position of a set of images at right-angles to the maxilla at the site

geometry of view also can help evaluate a loss of vertical dimension, skeletal arch interrelationship, anterior crown/implant ratio, soft tissue profile, anterior tooth position in the prosthesis, and resultant moment of forces. As result, cephalometric radiographs are a useful tool for the development of an implant treatment plan, especially for the edentulous patient. However, this technique is not useful for demonstrating bone quality and only demonstrates a cross-sectional image of the alveolus where the central x-ray device are target to the alveolus.<sup>10</sup>

#### **Tomography: (figure 6)**

Tomography is a generic term formed from the Greek words tomo (slice) and graph



(picture) that was adopted in 1962 by the International commission on Radiological units and Measurements to describe all forms of body section radiography. Body section radiography is a special x-ray technique that enables visualization of a section of the patient's anatomy by blurring regions of the patient's anatomy above and below the section of interest.<sup>11,12</sup> In conventional tomography, different types of motion of the x-ray tube and the film are employed: linear (the simplest), circular, trispiral, elliptical and hypocycloidal. The images generated by complex motion tomography are generally sharper than those generated by linear tomography.<sup>4</sup>

In linear tomography, the thickness of the image layer depends on the angle of rotation of the x-ray tube. When the path of the x-ray tube is short, i.e., the angle is small, the image layer is relatively thick. As the path of movement is increased, the image layer decreases. Based on this principle, there are 2 types of tomography: Wide-angle tomography and narrow-angle tomography.<sup>13</sup> The main disadvantage of linear tomograms is the blurring of objects outside the focal plane, which produces "streak artifacts". These artifacts can be avoided by using Complex motion tomography: In most complex motion tomographic machines, tube and cassette motion is controlled by a computer, and is also called computer assisted tomography (figure 4). Computer-assisted tomography has become popular in implant and temporomandibular joint.

#### **Computed Tomography (Figs 7)**

Computed tomography (CT) is a digital and mathematical imaging technique that creates tomographic sections where the tomographic layer is not contaminated by blurred structures from adjacent anatomy. CT produces axial images of a patient's anatomy. CT images are inherently three-dimensional digital images typically 512 by 512 pixels with a thickness described by the slice spacing of the imaging technique. The individual element of the CT image is called a voxel, which has a value referred to in Hounsfield units, that describes the density of the CT image at that point. Each voxel contains 12 bits of data and ranges from -1000 (air) to + 3000 (enamel/dental materials) Hounsfield units. CT scanners are standardized at a Hounsfield value of 0 for water. CT can be used for imaging the temporomandibular joint, evaluating

dental/ bone lesions, assessing maxillofacial deformities, and for preand postsurgical evaluation of the maxillofacial region. CT provides reformatted image data to create tangential and crosssectional tomographic images of the implant site. With current generation CT scanners, reformatted images are characterized by a section thickness of 1 pixel (0.25 mm) and an in-plane resolution of 1 pixel by the scan spacing (0.5 to 1.5 mm) producing a geometric resolution similar to that of planar imaging. The density of structures within the image is absolute and quantitative and can be used to differentiate tissues in the region and characterize bone quality. The information provided is a life size image, which is highly desirable for ease of measurements.<sup>14</sup>

#### **Recent advances in computed tomography**

Cone beam CT: It uses a conical beam and reconstructs the image in any direction using special software. It gives all the information of a CT but, at 1/8 th the radiation dose and at a lower cost.<sup>15</sup> Microtomograph, another modification of CT is especially useful in acquiring serial sections of bone-implant interface. Multislice helical CT: It offers higher accuracy of images when compared to CT< 1508 the advantages of this type of imaging were evident and the limitations of delivery clear, which spawned the development of a number of techniques, referred to generically as 'Dentascanning Imaging'.<sup>16</sup>

#### **Interactive computed tomography**

The utility for dental implant treatment planning was evident, but the access to this imaging technique was evident. After receiving the CT films or prints of the patients, a clinician assesses potential implant site and locates vital structures. Sometimes it becomes difficult to locate these structures with accuracy without access to the original digital images and a diagnostic CT workstation that takes advantage of dynamic range of CT scan. Second, the implantologist decides which size implants to place, either by measuring directly from the film with a ruler or by placing an implant template on the film. This becomes more difficult if the CT scan image is not life sized. Thirdly, the three dimensional understanding of patient's anatomy is difficult from the series of cross-reference two-dimensional images. Finally, the quantitative assessment of bone density is not possible.<sup>17</sup>

An important feature of ICT is that the clinician and radiologist can perform “electronic surgery” (ES) by selecting and placing arbitrary size cylinders that simulate root form implants in the images. With an appropriately designed diagnostic template, ES can be performed to electronically develop the patient’s treatment plan in three-dimensions. Electronic implants can be placed at arbitrary positions and orientations with respect to each other, the alveolus, critical structures, the prospective occlusion and esthetics. ES and ICT enable the development of a three-dimensional treatment plan that is integrated with the patient’s anatomy and can be visualized before implant surgery by the members of the implant team and the patient for approval or modification. ICT enables the determination of bone quality adjacent to the prospective implant sites. With the number and size of implants accurately determined, along with the density of bone at the proposed implant sites, characteristics of the implants can be accurately determined before surgery. Currently ICT is the most accurate imaging technique for implant imaging and surgery but suffers some limitations<sup>18</sup>.

#### **Tuned Aperture Computed Tomography (TACT)**

TACT is a new and promising method for dentoalveolar imaging based on optical aperture theory. This technique uses information collected by passing a radiograph beam through an object from several different angles. A prototype developed for dental applications has a cluster of small radiograph tubes that can be fired in close sequence. The relationship of the source and the object can be used to determine projection geometry after the exposure is complete. TACT can map the incrementally collected data into a single 3- dimensional matrix. It can isolate the images of desired structures limited to certain depths. It has the ability to accommodate patient’s motion between exposures. It has considerable flexibility to adjust contrast and resolution.<sup>19</sup>

#### **Magnetic resonance imaging (fig.8)**

Magnetic resonance imaging (MRI) is based on the phenomenon of nuclear magnetic resonance (NMR). First described in 1946, its application in implantology is however of recent origin.<sup>20</sup> Magnetic resonance imaging is a CT imaging technique that produces images of thin

slices of tissues with excellent spatial resolution.

MRI allows complete flexibility in the positioning and angulation of image sections and can reproduce multiple slices simultaneously. Digital MRI images are characterized by voxels with an in-plane resolution measured in pixels (521x512) and millimeters (2 to 3 mm) for high resolution imaging acquisitions. The image sequences used to obtain magnetic resonance images can be varied to obtain fat, water, or balanced imaging of the patient’s anatomy. The images created by MRI are the result of signals generated by hydrogen protons in water or fat such that cortical bone will appear black (radiolucent) or as having no signal. Cancellous bone will generate a signal and will appear white because it contains fatty marrow. Metal restorations will not produce scattering and thus will appear as black images. Therefore MRI has been shown to be less prone to artifacts from dental restorations, prostheses, and dental implants than CT scans. As with CT, MRI is a quantitatively accurate technique with exact tomographic sections and no distortion. MRI may be used in implant imaging as a secondary imaging technique when primary imaging techniques such as complex tomography, CT or ICT fail. Complex tomography fails to differentiate the inferior alveolar canal in 60% of implant cases, and CT fails to differentiate the inferior alveolar canal in about 2% of implant cases. Double scout MRI protocols with volume and oriented cross-sectional imaging of the mandible produce orthogonal quantitative contiguous images of the proposed implant sites.<sup>21</sup>

## **CONCLUSION**

Implantologists and radiologists now have a variety of imaging modalities to rely on, however they should select proper modalities by relying on their knowledge of the advantages and limitations of the modalities. The excellent imaging modalities that exist today can certainly enhance the success of implant placement.

## **REFERENCES**

1. Bhat S, Shetty S, Shenoy KK. Imaging in Implantology. *J Indian Prosthodontic Society*. 2005; 5:10-4.
2. Frederickson NL. Diagnostic imaging in dental



- implantology. *Oral Surg Oral Med Oral Pathol Oral Radiol Endod.* 1995; **80**:540-1.
3. Tyndall AA, Brooks SL. Selection criteria for dental implant site imaging: a position paper of the American Academy of Oral and Maxillofacial radiology. *Oral Surg Oral Med Oral Pathol Oral Radiol Endod.* 2000; **89**:630 - 37.
4. Palmer RM, Smith BJ, Howe LC, Palmer PJ. Treatment planning: general considerations. In: Palmer RM, Smith BJ, Howe LC, Palmer PJ, editors. *Implants in clinical dentistry*. London: Martin Dunitz Ltd, 2002.
5. Misch CE. Density of bone: effect on treatment plans, surgical approach, healing and progressive bone loading. *Int J Oral Implant* 1990; **6**(2):23-31.
6. Miles D.A, Van Dis M.L. Implant Radiology. *Dental Clinics of North America* 1993; **37**(4):645-68.
7. Mallya S.M., Potluri A. Diagnostic imaging for implants. *JIAOMR* 2004; **16**(3):174-79.
8. Mupparapu M, Singer SR. Implant imaging for the dentist. *J Can Dent Assoc.* 2004; **7**(1): 32 – 32g.
9. Reiskin AB. Implant Imaging. *Dental Clinics of North America* 1998; **42**(1): 47-56.
10. Lekholm U. The surgical site. In: Lindhe J, Karring T, Lang NP, editors. *Clinical periodontology and implant dentistry*. Copenhagen: Munksgaard, 1997.
11. Pharoah MJ. Imaging techniques and their clinical significance. *Int J Prosthodontics*. 1993; **6**: 176 - 79.
12. Shetty V, Benson BW. Orofacial Implants. In White SC, Pharoah MJ, editors. *Oral Radiology: principles and interpretation*. 5th edition, St. Louis: Mosby, Inc; 2004. pp 677-92.
13. Hendrick RT, Dove SB, Peters DD. Radiographic determination of canal length: direct digital radiography versus conventional radiography. *J Endodont.* 1994; **20**(7): 320 -26.
14. Scaf G Et al. Dosimetry and Cost of imaging osseointegrated implants with film-based and computed tomography. *Oral Surg Oral Med Oral pathol Oral Radiol Endod.* 1997; 123-27.
15. Jeffcoat MK: Application of digital radiography to implantology. *J Dent Symp.* 1993; **1**: 30-33.
16. Divya Kalra, Geetika Jain, Abhijeet Deoghare, Pravin Lambade. Role of imaging implants. *Journal of Indian Academy of Oral Medicine and Radiology*; 2010; **22**(1):34-38
17. Sennerby L, Wennerberg A. A new microtomographic technique for non-invasive evaluation of the bone structure around Implants. *Clin Oral Implants Res* 2001; **12**: 91.
18. Naitoh M, Katsumata A. Measurement accuracy of reconstructed 2-D images obtained by multi-slice helical computed tomography: *Clin Oral Implants Res* 2004; **15**: 570.
19. Webber RL, Horton RA. Comparison of film, direct digital and TACT images to identify the location of crestal defects around endosseous titanium implants. *Oral Surgery Oral Medicine Oral Pathology* 1996; **81**:480-90.
20. Gray CF, Red path TW, Smith FW. Low field Magnetic Resonance imaging for Implant Dentistry. *Dentomaxillofacial Radiol.*, 1998; **27**: 225-29.
21. Zabalegui J, Gil JA, Zabalegui B. Magnetic resonance imaging as an adjunctive diagnostic aid in patient selection for endosseous implants: preliminary study. *Int J Oral Maxillofac Impl.* 1991; **5**: 283 - 88.
22. Busnur Shilpa Jayadevappa, Kodhandarama Gs. Imaging of dental implants. *Journal of Oral Health Research*, 2010; **1**(2).