

## A Case-report on Periodontal Abscess of a Single Tooth in an Otherwise Healthy Dentition: A Treatment Approach

J. Bhuvaneswarri, V. Ramya, N. Manisundar and Preethepaddmanabhan

Department of Periodontics, Sree Balaji Dental College & Hospital,  
Bharath University, Chennai, India.

[dx.doi.org/10.13005/bbra/1267](https://doi.org/10.13005/bbra/1267)

(Received: 10 January 2014; accepted: 05 February 2014)

**This article describes a simple procedure for hemisection in mandibular molar and its restoration, of periodontally diseased teeth with severe bone loss may well be retained by removal of one or more of their roots.**

**Key words:** Hemisection, Vertical root fracture.

Modern advances in all phases of dentistry have provided the opportunity for patients to maintain a functional dentition for lifetime. Therapeutic measures performed to ensure retention of teeth vary in complexity. The treatment may involve combining restorative dentistry, endodontics and periodontics so that the teeth are retained in whole or in part. Such teeth can be useful as independent units of mastication or as abutments in simple fixed bridges. Continued periodontal breakdown may lead to total loss of tooth unless these defects can be repaired or eliminated and health of the tissues restored. Thus tooth resection procedures are used to preserve as much tooth structure as possible rather than sacrificing the whole tooth<sup>[1]</sup>. The term tooth resection denotes the excision and removal of any segment of the tooth or a root with or without its accompanying crown portion.<sup>[4]</sup> Various resection procedures described are: root amputation, hemisection, radisection and

bisection. Root amputation refers to removal of one or more roots of multirooted tooth while other roots are retained.

Hemisection denotes removal or separation of root with its accompanying crown portion of mandibular molars. Radisection is a newer terminology for removal of roots of maxillary molars. Bisection / bicuspidization is the separation of mesial and distal roots of mandibular molars along with its crown portion, where both segments are then retained individually<sup>3</sup>.

Weine has listed the following indications for tooth resection<sup>2</sup>

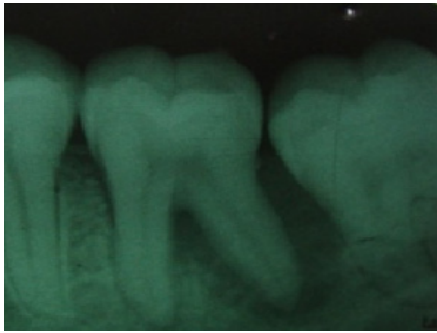
### Periodontal indications

1. Severe vertical bone loss involving only one root of multi-rooted teeth.
2. Through and through furcation destruction.
3. Unfavourable proximity of roots of adjacent teeth, preventing adequate hygiene maintenance in proximal areas.
4. Severe root exposure due to dehiscence.

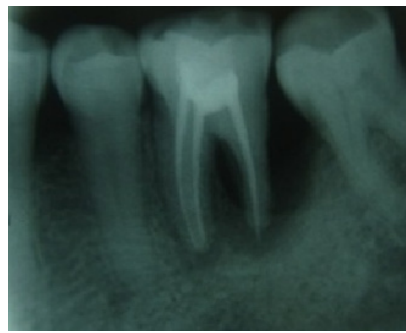
### Other indications<sup>7</sup>

1. Prosthetic failure of abutments within a splint: If a single or multirooted tooth is periodontally involved within a fixed bridge, instead of removing the entire bridge, if the remaining abutment support is sufficient, the

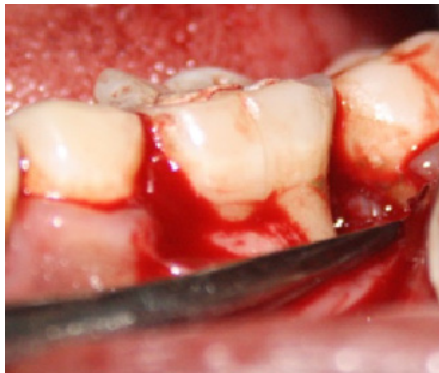\* To whom all correspondence should be addressed.  
Tel.: +91-9962101341;  
E-mail: drbhuvana22@gmail.com



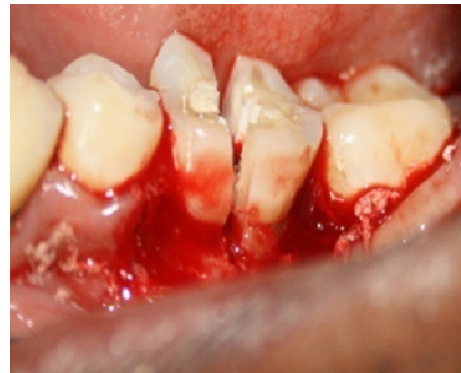**Fig. 1.** Preoperative



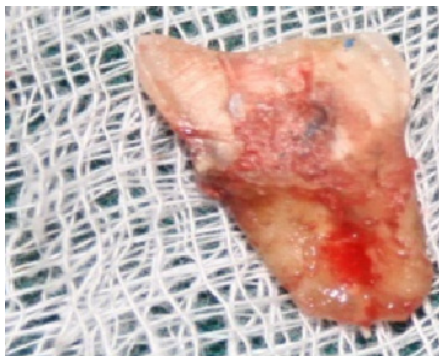**Fig. 2.** After obturation



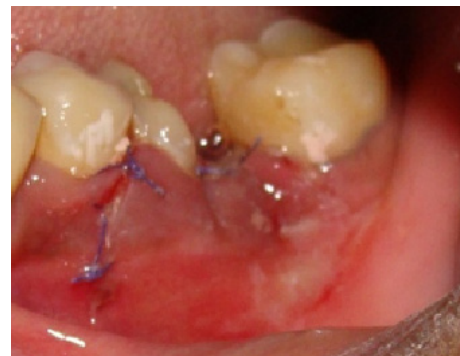**Fig. 3.** After flap retraction



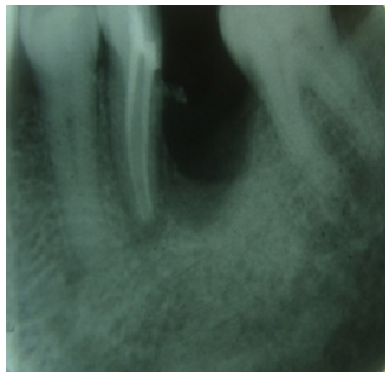
**Fig. 4.** After hemisection



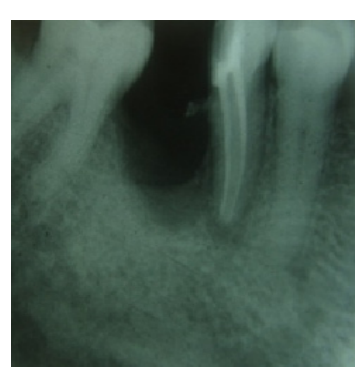
**Fig. 5.** Hemisected distal root



**Fig. 6.** After suture



**Fig. 7.** Immediatepostoperative



**Fig. 8.** Postoperative after months

- root of the involved tooth is extracted
2. Endodontic failure: Hemisection is useful in cases in which there is perforation through the floor of the pulp chamber, or pulp canal of one of the roots of an endodontically involved tooth which cannot be instrumented.
  3. Vertical fracture of one root: The prognosis of vertical fracture is hopeless. If vertical fracture traverses one root while the other roots are unaffected, the offending root may be amputated.
  4. Severe destructive process: This may occur as a result of furcation or sub. Gingival caries, traumatic injury, and large root perforation during endodontic therapy.

#### **Contra indications<sup>8</sup>**

- a. Strong adjacent teeth available for bridge abutments as alternatives to hemisection.
- b. Inoperable canals in root to be retained.
- c. Root fusion-making separation impossible.

#### **Case report**

A 30 years old man reported with the complaint of pain and mobility of left mandibular first molar. On examination, the tooth was sensitive to percussion and revealed grade II mobility. On probing the area, there was a 13 mm deep periodontal pocket around the distal root of the tooth.

On radiographic examination, severe vertical bone loss was evident surrounding the distal root and involving the furcation area. In the mesial root bone was completely intact (Fig. 1). It was decided that the distal root should be hemisected after completion of endodontic therapy of the tooth (Fig: 2) The working length was determined and the canals were biomechanically prepared using stepback technique. The canals were obturated with lateral condensation method and the chamber was filled with amalgam to maintain a good seal and allow interproximal area to be properly contoured during surgical separation.

Under local anesthesia, full thickness flap was reflected after giving a crevicular incision from first premolar to second molar (Fig:3). Upon reflection of the flap, the bony defect along the distal root became quite evident. All chronic inflammatory tissue was removed with curettes to expose the bone.

The vertical cut method was used to resect

the crown. A long shank tapered fissure carbide bur was used to make vertical cut toward the bifurcation area. A fine probe was passed through the cut to ensure separation (Fig: 4), the distal root was extracted and the socket was irrigated adequately with sterile saline to remove bony chips and amalgam debris (Fig. 5).

The furcation area was trimmed to ensure that no spicules were present to cause further periodontal irritation. Scaling and root planning of the root surfaces, which became accessible on removal of distal root was done. The extraction site was irrigated and debrided & autogenous bone graft was placed and the flap was then repositioned and sutured with 3/0 black silk sutures (Fig:6). The occlusal table was minimized to redirect the forces along the long axis of the mesial root. (Fig: 7) showing immediate postoperative radiograph & (Fig: 8) radiograph showing postoperative after 3 months. After healing of the tissues, fixed bridge involving retained mesial half and mandibular second molar with sanitary pontic has to be given.

#### **DISCUSSION**

Success of root resection procedures depend, to a large extent, on proper case selection. It is important to consider the following factors before deciding to undertake any of the resection procedures.<sup>[6]</sup>

- 1) Advanced bone loss around one root with acceptable level of bone around the remaining roots.
- 2) Angulation and position of the tooth in the arch. A molar that is buccally, lingually, mesially or distally tilted, cannot be resected.
- 3) Divergence of the roots - teeth with divergent roots are easier to resect. Closely approximated or fused roots are poor candidates.
- 4) Length and curvature of roots - long and straight roots are more favourable for resection than short, conical roots.
- 5) Feasibility of endodontics and restorative dentistry in the root/roots to be retained.

Hemisection has been used successfully to retain teeth with furcation involvement. However, there are few disadvantages associated with it. As with any surgical procedure, it can cause pain and

anxiety. Root surfaces that are reshaped by grinding in the furcation or at the site of hemisection are more susceptible to caries. Often a favorable result may be negated by decay after treatment. Failure of endodontic therapy due to any reason will cause failure of the procedure. In addition, when the tooth has lost part of its root support, it will require a restoration to permit it to function independently or to serve as an abutment for a splint or bridge.

<sup>[4]</sup> Unfortunately, a restoration can contribute to periodontal destruction, if the margins are defective or if non-occlusal surfaces do not have physiologic form. Also, an improperly shaped occlusal contact area may convert acceptable forces into destructive forces and predispose the tooth to trauma from occlusion and ultimate failure of hemisection. Occlusal function such as location and size of contacts and the steepness of cuspal inclines may have played a significant role in causing mobility before treatment<sup>[3]</sup>. During treatment, occlusal contacts were reduced in size and repositioned more favorably. Lateral forces were reduced by making cuspal inclines less steep and eliminating balancing incline contacts.

### CONCLUSION

The prognosis for hemisection is the same as for routine endodontic procedures provided that case selection has been correct, the endodontics has been performed adequately, and the restoration is of an acceptable design relative to the occlusal and periodontal needs of the patient. Root amputation and hemisection should be considered as another weapon in the arsenal of the periodontist,

determined to retain and not remove the natural teeth. With recent refinements in endodontics, periodontics and restorative dentistry, hemisection has received acceptance as a conservative and dependable dental treatment and teeth so treated have endured the demands of function.

### REFERENCES

1. Basaraba, N., "Root Amputation and Tooth Hemisection." *Dental Clinics of North America* 1969; **13**(1): 121–32.
2. Weine, Franklin S., *Endodontic Therapy*. St. Louis [Mo.]: Mosby, 1996.
3. Ingle, John Ide, Leif K Bakland, J. Craig Baumgartner, and John Ide Ingle., *Ingle's Endodontics 6*. Hamilton, ON; Maidenhead: BC Decker/ ; McGraw-Hill Education [distributor], 2008.
4. Carranza, Fermin A, and Irving, Newman, Michael G Glickman., *Clinical Periodontology*. Philadelphia [u.a.: Saunders, 1996.
5. Staffileno, H J., "Surgical Management of the Furca Invasion." *Dental Clinics of North America* 1969; **13**(1): 103-19.
6. Kost, W J, and J E Stakiw., "Root Amputation and Hemisection." *Journal (Canadian Dental Association)* 1991; **57**(1): 42-45.
7. Biesterfeld, R C, and J F Taintor., "Endodontic Considerations Related to Hemisection and Root Amputation." *Northwest Dentistry* 1978; **57** (3): 142–48.
8. Ross, I F, and R H Thompson Jr., "A Long Term Study of Root Retention in the Treatment of Maxillary Molars with Furcation Involvement." *Journal of Periodontology* 1978; **49**(5): 238–44. doi:10.1902/jop.1978.49.5.238.