

Lateral Submental Intubation in Panfacial Trauma Review of Five Cases

Balakrishnan Ramalingam, Vijay Ebenezer and Abu Dakir

Department of Oral and Maxillofacial Surgery,
Sree Balaji Dental College and Hospitals, Bharath University, Chennai, India.

doi: <http://dx.doi.org/10.13005/bbra/1356>

(Received: 02 March 2014; accepted: 04 April 2014)

Maintaining the airway while operating panfacial trauma patients is very crucial and important. Panfacial trauma may include cranial fractures, nasal fractures along with maxillomandibular fractures. The conventional oroendotracheal intubation is contraindicated since the tube will hinder the maxillomandibular fixation by wiring or while reducing and stabilising the fractured segments. Nasoendotracheal intubation is also not a choice of intubation since the nasal fractures are also present in a panfacial fracture. Even it can cause meningitis or the tube can be passed intracranially in patients with frontobasilar fractures. Only option for maintaining the airway remained complex procedures like tracheostomy or cricothyrotomy until 1986 when a Spanish maxillofacial surgeon named Francisco Hernandez Altemir invented an alternate way known as submental intubation for airway maintenance after intubation. In submental intubation at first the normal orotracheal intubation is done followed by which an incision is placed at the submental region and blunt dissection is made through which the tube is passed from inside to outside and then reconnected. It is an excellent method of intubation for panfacial trauma since it does not interfere with the treatment or surgical procedures

and at the same time complicated procedures like tracheostomy. Several modifications are available for the submental intubation. Five cases of maxillomandibular fractures along with nasal fractures are operated successfully while using the lateral submental intubation approach for maintaining the airway.

MATERIALS AND METHOD

These aims were kept in mind while following the procedures namely feasibility, safety of the patients, reliability, to avoid tracheostomies, to make the surgical work easier in selective surgical cases. The patients who were selected for submental intubation included the following criteria : maxillofacial trauma with associated nasal bone fracture, maxillofacial trauma with associated skull base fractures, use of temporary intermaxillary fixation in patients where nasotracheal intubation is not possible, complex orthognathic surgery, in cleft patients with simultaneous rhinoplasty, patients with minimal neurological deficit, patients with large pharyngeal flaps, Le fort III fractures. The exclusion criteria are : gun shot injuries in maxillofacial region, long term airway maintenance, tumour ablation in maxillofacial region, patients with severe neurological deficit, patients with multi system trauma, known severe keloid formers.

Procedure

Local anesthesia was administered in the submental region with 2% lignocaine with 1:80000

* To whom all correspondence should be addressed.

adrenaline. Surgical skin preparation of the perioral and submental region was performed. The author followed the “2-2-2” rule and an incision measuring approximately 2cm was made 2cm to the lateral border of the mandible in the submental region. Conventional orotracheal intubation was done. The lower medial mandibular edge to be identified using a curved haemostat. The mouth opening was maintained by a suitable prop. The floor of the mouth was exposed by retracting the tongue. An incision was made intraorally parallel to the gingival margin measuring about 2cm. A blunt dissection was done using an artery forceps initially and then the mylohyoid muscle to be bluntly dissected. The haemostat then was passed readily into the oral cavity after passing

through the mucosa in the floor of the mouth. The pneumatic was momentarily deflated, caught with artery forceps and then passed first through the space followed by the endotracheal tube itself. The tube was cleaned with gauze to remove the blood which may cause hindrance. The anaesthetist then reattached the tube to Boyle’s apparatus. The tube was secured in position in the submental region with interrupted sutures using 3-0 black silk material. At the termination of the surgical procedure the pneumatic cuff and the endotracheal tube was passed back through the incision into the mouth, reversing the original pathway. They are then exited through the mouth and secured. The extraoral submental wound was sutured using 3-0 silk with simple interrupted sutures,

Case 1: Orthognathic surgery

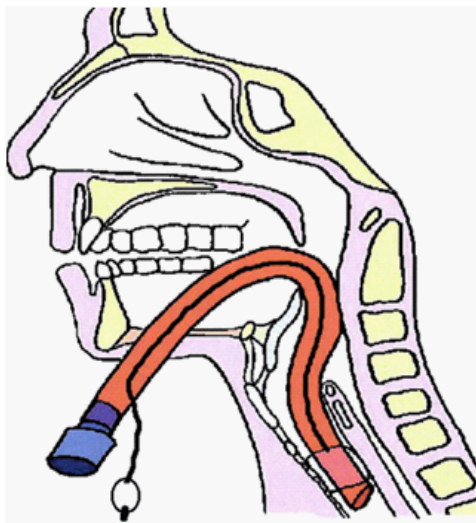


Fig. 1. Schematic diagram

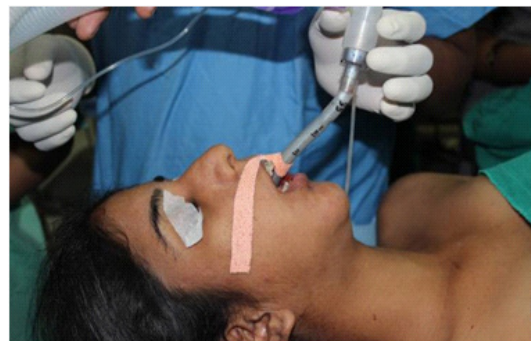

Fig. 2. Oroendotracheal intubation

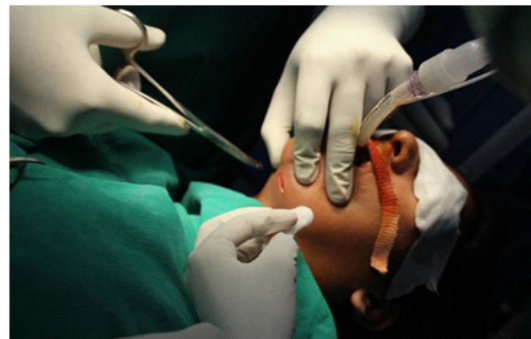
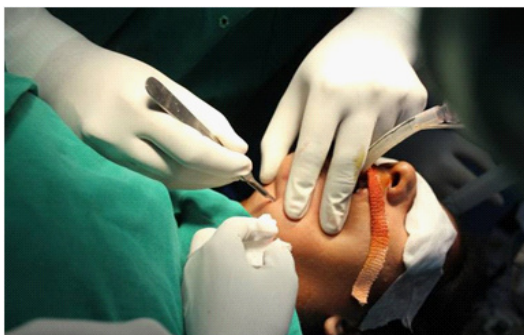

Fig. 3-4. Incision measuring approximately 2cm was made 2cm to the lateral border of the mandible in the submental region

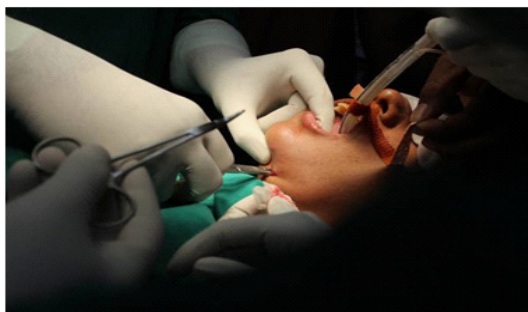


Fig. 5. Blunt dissection

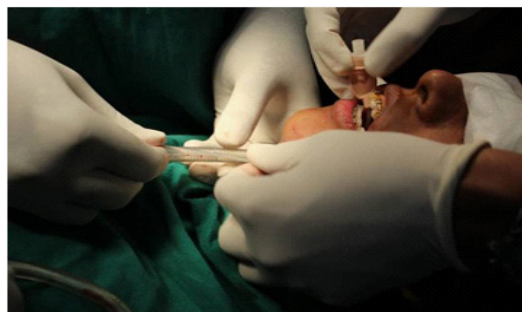


Fig. 6. Tube passed through the submental region

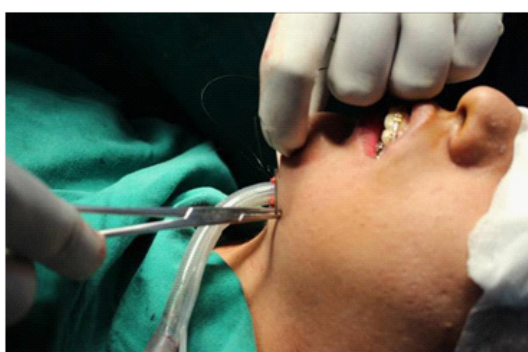


Fig. 8. Tube stabilised with 3-0 black silk suture

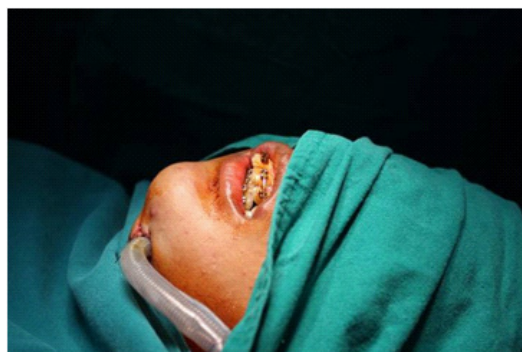

Fig. 9. Suturing done

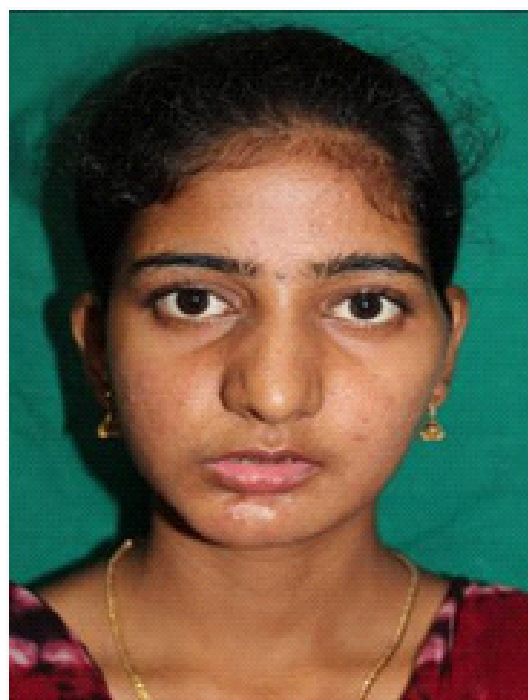
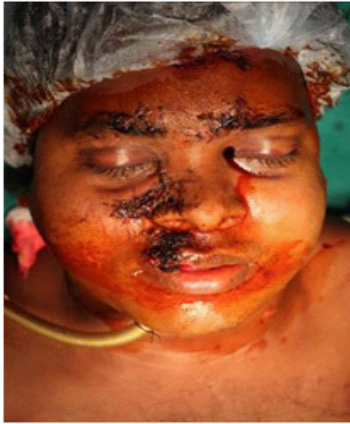
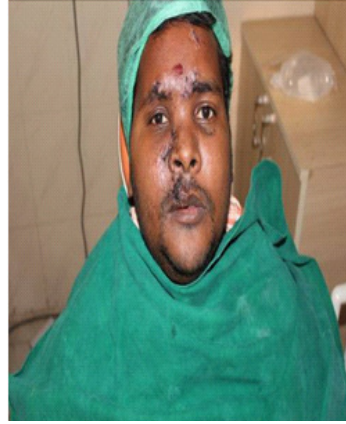
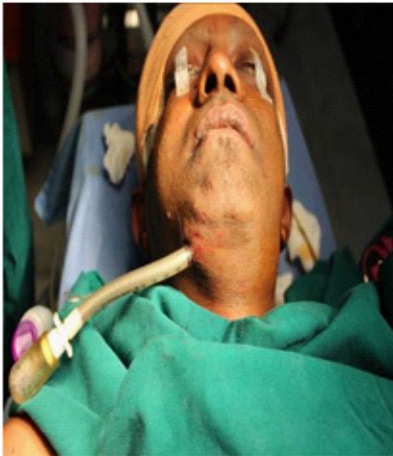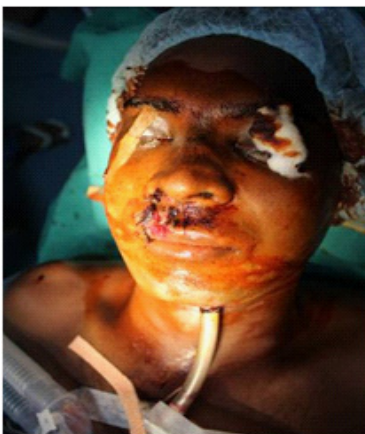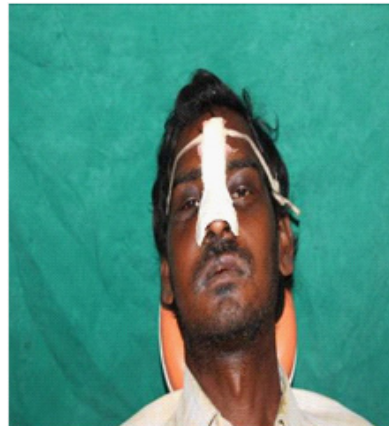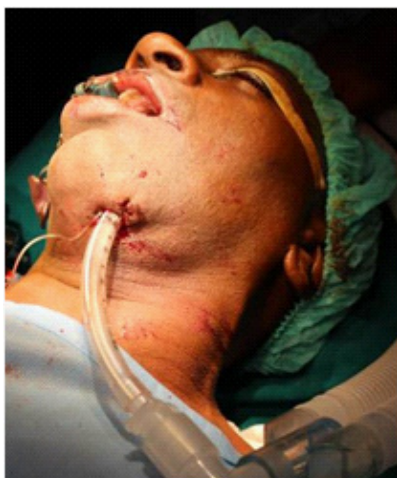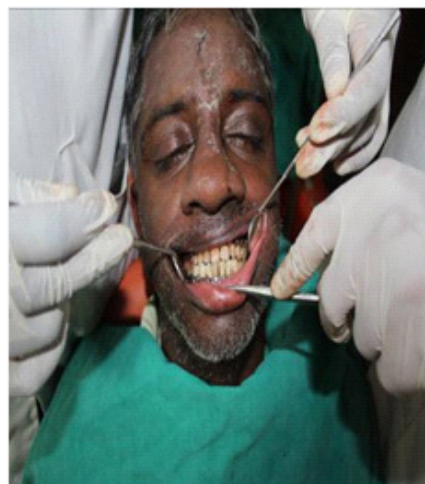
Fig. 10. Postoperative

without seeking a taut closure in order to allow thereby a certain degree of drainage. Postoperative antibiotics and anti-inflammatory drugs were administered.

DISCUSSION

The submental route was developed by Alteimer in 1986 for endotracheal intubation with intention of avoiding tracheostomies and to make surgical work easier in chosen cases.⁽¹⁾ Thus it removes the possibility of the tube interfering with the surgical field. Alteimer studied more regarding the submental intubation in the following years.^(2,3,4) Bartkowski did further studies.⁽⁵⁾ During panfacial fracture cases including skull base fractures, nasal fractures and maxillomandibular fractures the following problems may arise. In case of cranial fractures nasoendotracheal intubation may lead to cranial intubation when the frontobasillar fracture is present along with nasoethmoidal complex fracture. In case of nasal fracture nasoendotracheal intubation may lead to epistaxis, trauma to the pharynx, pressure necrosis

Case 2. Lefort ii fracture with nasoethmoidal complex fracture**Fig. 11.** Intraoperative**Fig. 12.** Postoperative**Case 3.** Lefort ii fracture, zygomatic arch fracture with ethmoidal bone fracture**Fig. 13.** Intraoperative**Fig. 14.** Postoperative**Case 4.** Lefort II fracture with nasoethmoidal complex fracture**Fig. 15.** Intraoperative**Fig. 16.** Postoperative

Case 5. Lefort III fracture**Fig. 17.** Intraoperative**Fig. 18.** Postoperative

of the external nares, otitis media, sinusitis, sepsis and inability to press the tube in the nasal passages.^(6,7,8) In case of maxillomandibular fractures oroendotracheal intubation faces the complication of hindrance to the surgical field which might need maxillimandibular fixation with arch bars and wires.

To avoid these complications the alternative ways of maintaining the airway are the tracheostomy, retromolar intubation and the nasal tube shift technique. Tracheostomy includes the possibilities of general, local, early and late complications. General complications include cardiac arrest due to stimulation of vagus nerve, post hypercapnic shock due to sudden lowered carbon dioxide level and aeroembolism. Local complications include hemorrhage, subcutaneous or mediastinal emphysema and recurrent laryngeal nerve damage.^(9,10) Late complications may include laryngeal or tracheal stricture, hemorrhage from large blood vessels, trachea oesophageal fistula and inflammatory complications.⁽¹¹⁾ The retromolar intubation poses the complications of severe bleeding, technique sensitiveness, specialized instrumentation and the operation being time consuming.⁽¹²⁾ The nasal tube shift technique is also not preferable due to complications associated with intraoperative reintubation which includes risk of aspiration due to posterior nasal bleeding, potential airway compromise, unfavourable

manipulation of an unstable cervical spine and excessive stress on fixation with possible loosening of plates and screws.^(13, 14)

Thus submental intubation becomes the choice of intubation technique in these cases. Several modifications to the original submental intubation technique have been tried and studied^(15,16,17,18,19,20). The author used the modified lateral submental intubation technique^(21,22). The technique requires no other equipment than the normally used instruments like BP blade and handle, hemostat, scissors, needle holder and 3-0 silk sutures. The lateral submental intubation technique is designed so that the geniohyoid and genioglossus muscles do not have to be crossed thus easily sparing the insertion of the anterior belly of digastric muscle. Also damaging important structures like wharton's duct and their orifices, the lingual nerve, the sublingual and submaxillary glands are avoided through this lateral submental technique. Hence the endotracheal tube passes through a space which is related to the anterior belly of digastric muscle, the most anteroir portion of mylohyoid muscle and the lower edge of mandible paramedially. This typical surgical manoeuvres of oarl and maxillofacial surgery can be done without the interference of intubation through the natural orifices and without having to resort to tracheostomy. Henceforth the advantages of submental intubation can be summarised as

: It is a simple and successful procedure with low failure rate. It allows surgical access to the maxillofacial structures without interference to intubation and without compromising the surgery and maxillo-mandibular fixation. It avoids complications inherent to nasotracheal intubation and tracheostomy for airway management of patients with severe midfacial fractures. It leads to an aesthetic scar. The operative and intubation procedure was completed within few minutes. There is minimal bleeding during which the airway was never compromised. Controlled mechanical ventilation could be done in the usual way throughout the reconstructive surgery. The planned reconstructive surgery could be completed in every patient.

CONCLUSION

All the above mentioned cases were treated successfully under general anaesthesia using the lateral submental intubation technique. Considering the excellent results of a hindrance and complication free surgical field, an aesthetic scar and less morbidity along with the aforementioned advantages lateral submental intubation technique is one of the best alternative ways of intubation while treating panfacial fracture cases.

REFERENCES

1. Francisco Hernandez Altemir. The submental route for endotracheal intubation: A new technique. *J. cranio maxillofac. surg.* 1986; **14**: 64-65.
2. Francisco Hernandez Altemir. Pericranial fixation of the nasotracheal tube. *J.oral maxillofacial surg.* 1986; **44**: 585
3. Francisco Hernandez Altemir. Nasotracheal intubation in patients with facial fractures. *Plastic and reconstructive surgery.* 1992; **89**:165-166
4. Francisco Hernandez Altemir, sofia Hernandez Montero. The submental route revisited using the laryngeal mask airway. *J craniomaxillofac. surg.* 2000; **24**:343-344
5. Bartkowski-SB, zapala-J, Szuta-M, Podziorny-H, Kuchta-K, general anesthesia via tracheosubmental intubation from our own experience. *Aestheticplast-surg.* 1999; **23**(4): 292-5.
6. Schultz RC; Nasotracheal intubation in the presence of facial fractures; *Plat ReconstrSurg* 1990; **86**:1046.
7. Fonseca R, Walker R, Oral and Maxillofacial Trauma, 2nd edition, Philadelphia; WB Saunders 1997; 105-35.
8. Hall DB; Nasotracheal intubation with facial fractures; *JAMA*; 1989; **261**: 1198
9. Guckman JL; Mangal AK; Pharyngeal trauma in Paparella MM ; Shumrick DA; Gluckman JL; Meyerhoff WL; Editors; Otolaryngology vol 3 Head and Neck; Philadelphia; PA; *Saunders* 1991; p 2231
10. McClelland RM; Complications of tracheostomy; *Br Med J* 1965; **2**: 567.
11. Glazur J; Respiration via tracheostomy – Advantages, disadvantages and complications *Anesth Reanim* 1971; **3**: 451.
12. Martinez – Lge JL, Eslava JM; Cebrecos AI, Marcos O, Retromolar intubation; *J Oral Maxillofac Surg* 1998; **56**: 302-6
13. Werter JR *et al*; Nasal tube switch: Converting from nasal to an oral endotracheal tube without extubation; *J Oral Maxillofac Surg* 1994; **54**: 994-6
14. Premalatha M Shetty, Santosh Kumar Yadav, Madhusudhan Upadya; Submental intubation in patients with panfacial fractures; A prospective study; *IJA* 2011; **55**: 299-304
15. Prochno T, Dornberger I, Esser U. Management of panfacial fractures: Also an intubation problem. *HNO*. 1996; **44**:19– 21.
16. Green JD, Moore UJ. A modification of submental intubation. *Br J Anaesth.* 1996; **77**: 789–91.
17. Drolet P, Girard M, Poirier J, Grenier Y. Facilitating submental endotracheal intubation with an endotracheal tube exchanger. *Anesth Analg.* 2000; **90**: 222-3.
18. MacInnis E, Baig M. A modified submental approach for oral endotracheal intubation. *Int J Oral Maxillofac Surg.* 1999; **28**: 344-6.
19. Stoll P, Galli C, Wächter R, Bähr W. Submandibular endotracheal intubation in panfacial fractures. *J Clin Anesth.* 1994; **6**: 83-6
20. Sonia Jindal, Kamlesh Kothari, and Amit Kumar Singh; Submental Intubation; *Dent Res J*; 2013; **10**(3): 401 -403.
21. Amin M, Dill-Russel P, Manisali M, Lee R, Sinton I. Facial fractures and submental intubation. *Anaesthesia.* 2002; **57**:1195–212.
22. Ramesh Kumar Sharma *et al*; Submental tracheal intubation in oromaxillofacial surgery; *Indian J Plast Surg*; 2008; **41**(1): 15-19.